# REPORT DOCUMENTATION PAGE

OMB No. 0704-0188

Public reporting burden for this collection of information is estimated to average 1 hour per response, including the time for reviewing instructions, searching existing data sources, gathering and maintaining the data needed, and completing and reviewing the collection of information. Send comments regarding this burden estimate or any other aspect of this collection of information, including suggestions for reducing this burden, to Washington Headquarters Services, Directorate for Information Operations and Reports, 1215 Jefferson Davis Highway, Suite 1204, Arlington, VA 22202-4302, and to the Office of Management and Budget, Paperwork Reduction Project (0704-0188), Washington, DC 20503.

1. AGENCY USE ONLY (Leave blank)

2. REPORT DATE: April 3, 1995

3. REPORT TYPE AND DATES COVERED

4. TITLE AND SUBTITLE: Interpretation of Chemically Created Periapical Lesions Using Direct Digital Imagining

5. FUNDING NUMBERS

6. AUTHOR(S): Allen W. Meier

7. PERFORMING ORGANIZATION NAME(S) AND ADDRESS(ES)

AFIT Students Attending:
Indiana University School of Dentistry

8. PERFORMING ORGANIZATION REPORT NUMBER
AFIT/CI/CIA
95-041

9. SPONSORING/MONITORING AGENCY NAME(S) AND ADDRESS(ES)

DEPARTNEMT OF THE AIR FORCE
AFIT/CI
2950 P STREET, BDLG 125
WRIGHT-PATTERSON AFB OH 45433-7765

10. SPONSORING/MONITORING AGENCY REPORT NUMBER

DTIC ELECTE JUL 19 1995 S D G

11. SUPPLEMENTARY NOTES

12a. DISTRIBUTION/AVAILABILITY STATEMENT

Approved for Public Release IAW AFR 190-1
Distribution Unlimited
BRIAN D. GAUTHIER, MSgt, USAF
Chief Administration

12b. DISTRIBUTION CODE

13. ABSTRACT (Maximum 200 words)

DTIC QUALITY INSPECTED 1

14. SUBJECT TERMS

15. NUMBER OF PAGES: 110

16. PRICE CODE

17. SECURITY CLASSIFICATION OF REPORT

18. SECURITY CLASSIFICATION OF THIS PAGE

19. SECURITY CLASSIFICATION OF ABSTRACT

20. LIMITATION OF ABSTRACT

# DISCLAIMER NOTICE




THIS DOCUMENT IS BEST QUALITY AVAILABLE. THE COPY FURNISHED TO DTIC CONTAINED A SIGNIFICANT NUMBER OF COLOR PAGES WHICH DO NOT REPRODUCE LEGIBLY ON BLACK AND WHITE MICROFICHE.

# INTERPRETATION OF CHEMICALLY CREATED PERIAPICAL LESIONS USING DIRECT DIGITAL IMAGING


| Accesion For | | |
|---|---|---|
| NTIS CRA&I | | ☒ |
| DTIC TAB | | ☐ |
| Unannounced | | ☐ |
| Justification | | |
| By | | |
| Distribution / | | |
| Availability Codes | | |
| Dist | Avail and / or Special | |
| A-1 | | |



by

Allen W. Meier


Submitted to the Graduate Faculty of the School of Dentistry in partial fulfillment of the requirements for the degree of Master of Science in Dentistry, Indiana University School of Dentistry, 1995.


19950718 037

Thesis accepted by the faculty of the Department of Endodontics, Indiana University School of Dentistry, in partial fulfillment of the requirements for the degree of Master of Science in Dentistry.

Dale A. Miles

Dale A. Miles

Susan L. Zunt

Susan L. Zunt

Phil P. Guba

Phil P. Guba

Joseph J. Legan

Joseph J. Legan

Cecil Brown

Cecil E. Brown, Jr.

Chairman of the Committee

Date April 3, 1995

# ACKNOWLEDGMENTS

The Biblical Psalmist once inquired of the Lord, "What is man that Thou art mindful of him?" He was rhetorically asking the reason for his life's blessings, undeserved as they were. I share the Psalmist's view that the great achievements of my life have been due primarily to the grace of the Lord and the helping hands of others. From Him all blessings flow, and many of them are evident in those I acknowledge here.

I am grateful to have had the opportunity to know and love my wife for nearly 12 years. She is the darling of my life; she amazes me daily with her patience, love, kindness, and understanding. I thank her and our two sons, Daniel and Timothy, for keeping my life in perspective while I wrestled with this project.

Dr. Cecil Brown has shepherded me through the maze of "clinicademia" with skill, forebearance and dry humor. His confidence in my future, when I often questioned it, will be forever appreciated.

Doctors Joe Legan and Al Dupont were never too busy to give sage advice and share a laugh. I will miss our lunchtime bantor.

Doctors Kenneth Spolnik, Duane Compton, Kevin Deardorf, William Adams, Phil Guba, Michael Keller, Dale Miles and Susan Zunt, in various ways and to various degrees, taught me the art of endodontics as well as the science. My wish is that those who see my work in the future will think as highly of my teachers as I do.

Without the enormous help and great patience of Doctor Mostafa Analoui, I would not have been able to complete this project, and possibly not even begin it. I only had to promise him a ride in an Air Force F-15. I'll get to work on that right away!

Residents may come and go, but Karen Bissonette keeps the graduate clinic moving. She endured my soapbox orations on the meaning of life and the absurdities of politics, all the while cheerfully running herself ragged helping us. She deserves high praise and a big raise.

To my fellow travelers Mu Mu Min, Bob Brandys, Jimmy Woods, Darin Kajioka and Ron Steinbrunner, I can only say how enjoyable you have made the journey. Your friendship and laughter have made even difficult days easier.

Thank you.

TABLE OF CONTENTS

Introduction ..... 1

Review of Literature ..... 5

Methods and Materials ..... 61

Results ..... 67

Figures and Tables ..... 70

Discussion ..... 82

Summary and Conclusions ..... 89

References ..... 93

Abstract ..... 106

Curriculum Vitae

# LIST OF ILLUSTRATIONS

FIGURE 1 Specimen mounted on paralleling device . . . . . 71

FIGURE 2 Examiner viewing arrangements . . . . . 72

FIGURE 3 Specimen C at 24 hours - linear setting . . . . . 73

FIGURE 4 Specimen C at 24 hours - reverse contrast . . . . . 74

FIGURE 5 Specimen C at 24 hours -pseudocolor enhancement . . . . . 75

FIGURE 6 Specimen C at 24 hours - global histogram equalization . . . . . 76

FIGURE 7 Specimen C at 24 hours - regional histogram equalization . . . 77

TABLE I Intrarater Reproducibility: Intraclass correlation coefficient . . . 78

TABLE II Intrarater Kappa Statistic: All times . . . . . 78

TABLE III Intrarater Kappa Statistic: Hour 0 . . . . . 79

TABLE IV Intrarater Kappa Statistic: Hour 24 . . . . . 79

TABLE V Interrater Variability: Intraclass correlation coefficient . . . . . 80

TABLE VI Interrater Kappa Statistic: All times . . . . . 80

TABLE VII Interrater Kappa Statistic: Hour 0 . . . . . 81

TABLE VIII Interrater Kappa Statistic: Hour 24 . . . . . 81

# INTRODUCTION

Dental radiographs often provide pivotal information in the diagnosis and treatment of periapical pathosis. The quality of the images, however, is greatly affected by exposure and development techniques, tissue density, and lesion size, location and character. Despite these variables, the radiograph is an indispensable tool for the clinician.

Radiographic detection of periapical pathology has been widely examined in the last few decades, but the results have been inconsistent. Researchers have still not conclusively determined what volume and character of bone (cortical versus medullary) must be lost before radiographic detection is possible. Seltzer and Bender's[1,2] 1961 studies suggested the cortical-medullary junction must be involved. However, Lee and Messer[3] concluded that 80 percent of lesions confined to medullary bone are detectable. These and other studies used surgical burs to create model lesions. A weakness of this mechanical approach is the production of a well-defined edge to the lesion border. True periapical breakdown stemming from pulpal pathology normally produces a ragged and more ill-defined border due to a host of immunologic, inflammatory and bacterial interactions. As noted by Tirrell,[4] chemically created lesions provide a way around this modeling problem by eliminating the sharp border.

Endodontic therapy has a lower success rate in those teeth with non-vital pulps and periapical rarefaction.[5,6] The first radiographically detectable, periapical evidence of pulpal necrosis is the so-called widened periodontal

ligament space, with or without loss of lamina dura. Earlier detection of periapical pathosis in an otherwise asymptomatic tooth would allow earlier intervention and possibly higher success rates in endodontic treatment of teeth with necrotic pulps.

Technological breakthroughs are now providing new options in radiographic quality, manipulation, and display. In 1989 Trophy USA introduced RadioVisioGraphy (RVG) to the dentists of North America.[7] Advantages of this and other direct digital imaging systems include high resolution and x-ray sensitivity, wide dynamic range, photometric accuracy and high signal-to-noise ratio.[8] The practical outgrowth of these characteristics is reduction of patient exposure to ionizing radiation, elimination of film processing delays, and manipulation of image contrast for improved diagnostic yield.[8]

The Trophy RVG system consists of a conventional x-ray generator connected to a microprocessor timer, a fiberoptically-coupled intraoral sensor (charge-coupled device or CCD) which replaces standard silver-halide radiographic film, and an image processor which captures the incoming signals, converting them for display on a high resolution monitor or other peripheral printer or transmitter.

Previously unimagined manipulation and enhancement of diagnostic images has been made possible through direct digital imaging. Pseudocolor enhancement is a well-established technique in medicine.[9] Recent studies have shown promising results in color-Doppler imaging and even magnetic resonance imaging. These methods take advantage of the "physiologic ability to discriminate color levels better than gray levels."[9] Very little information

exists about dental applications of pseudocolor enhancement. It was once written that the "perception of color and of hues of color is...of little interest in oral roentgenology."[10] This may no longer be true and needs to be tested.

Another method of image manipulation unavailable in standard film techniques is histogram equalization. In a linear RVG image the great majority of pixels (picture elements) render shades of gray near the extreme limits of the scale, i.e. most of the image is either very dark or very light, just as in a standard periapical radiograph. Histogram equalization allows creation of an image where all levels of gray are in equal proportion. This image processing technique is not in widespread clinical use, and its potential should be evaluated.

For this study, direct digital images of chemically-induced periapical lesions will be used to evaluate whether images modified by pseudocolor enhancement, contrast reversal or histogram equalization are more diagnostic than conventional images.

# REVIEW OF LITERATURE

## THE LAMINA DURA

It is well established that the bacterial and toxic products associated with pulpal death may exit the apical foramen and cause inflammation or infection of the periodontal ligament (PDL). This tissue membrane provides proprioceptive and nociceptive awareness and anchors the tooth in a way that allows physiologic movement within the socket. Sharpey's fibers from the PDL insert into the socket wall, which is known as the lamina dura when viewed radiographically.

When observed in a debrided and dried specimen, the tooth socket appears to have a relatively simple structure, that of a cortical-like thickening. Yet its nature, both biologic and radiographic, has been the source of debate.

In 1957 Goldman and associates[11] published their attempt to ascertain the registration of the architectural pattern of the cortical plates, the lamina dura and the interdental alveolar crest. They found that in both arches, the removal of the cortical plates had no effect on the radiographic trabecular pattern around the teeth or on the lamina dura and PDL space. They catalogued the various levels at which the lamina dura is continuous with the cortical plates. In all anterior teeth the buccal plates are continuous with the lamina dura, except at the apex. The lingual plate in the mandible shares this feature, but the maxillary lingual plate is only continuous with the lamina dura from about midroot. The cortical plates of the posterior mandible also join the lamina dura about midroot, but in the posterior maxilla there is much more variation. These researchers

believed that the quantity of bone, rather than its character, determined radiographic findings. They thought the lamina dura's radiographic visibility was due to socket shape: since the socket is oblong, rays are passing through many times the width of the alveolar bone. They compared this to the appearance of the mandibular inferior border, which also shows up as a radiopaque line.

In 1963 Manson[12] supported these ideas, stating that the white line visible radiographically "reflects a plate of bone through which rays must pass tangentially" leading to their attenuation. Therefore, Manson reasoned, the appearance of these lines is determined as much by the shape of the tooth root and its position relative to the beam as by the integrity of the osseous plate. He believed that a similar white line could be produced by artifact, and he cautioned clinicians to avoid critical interpretation of the lamina dura appearance or allow it to dictate treatment.

Part of Manson's arguments rested on his findings that the bone of the socket wall had the same mineral content as neighboring bone. In this, he supported the contentions of Goldman, Millsap and Brenman.[11] Kilpinin and Hakala[13] disagreed with this argument, claiming that the mineral content must differ from that of adjacent bone. They found it otherwise difficult to explain how beam direction could influence lamina dura visibility. They reasoned that since Sharpey's perforating fibers insert into this structure, it must be made of bundle bone, with a more highly calcified matrix than that of neighboring Haversian bone. As to its radiographic nature, they found that by removing the buccal and lingual plates of the mandible, the lamina dura lost some of its density, but not

its radiographic visibility. However, by drilling directly into the socket wall, the radiographic appearance was altered such that the lamina dura disappeared completely. Furthermore, they believed that certain disease entities could be used to bolster their argument for a higher mineral content within this radiographic thin white line. Hyperparathyroidism, a condition in which serum calcium is greatly elevated, causes a leaching of calcium from skeletal tissues. This decreased mineralization is classically manifested by the partial or complete disappearance of lamina dura from intraoral radiographs.[14] Kilpinin and Hakala contended that the nature of the lamina dura could thus be partially accounted for by its behavior.

Yet, even descriptions of its behavior must be clarified. Paris[15] reminded his readers that the term *lamina dura* is a radiographic expression only, and "neither a discrete organ nor a specialized tissue." He further stated that in the presence of a complete socket it is incorrect to describe a partial or complete "loss" of the lamina dura. His concern involved the inference that lamina dura interpretation was quantitative rather than qualitative. He suggested improving descriptive accuracy by adopting the radiographically correct "loss of definition" as a replacement for the inappropriate "loss of lamina dura."

That loss of definition could be due to many possible causes. Kaffee and associates[16] stated that lamina dura width and depth is related to vessel-encasing foramina, tooth position in the arch, the number of roots, the condition of the PDL, and angulation of the x-ray beam. They also noted that in any full mouth radiographic series, it is quite common to be unable to trace the lamina dura around every normal tooth. The absence of a definable lamina dura, if due

to pathology, may be partial or total. Pathological phenomena are usually local, but any differential diagnosis might include hyperparathyroidism, Paget's disease of bone, scleroderma, leukemia, Gaucher's disease, or diabetes. In some patients, physiologic forces may be to blame, rather than pathologic. Elfenbaum[17] explained that orthodontic forces will cause a change in lamina dura appearance, with the pressure side being thinned and the tension side becoming thicker.

Regardless of the above cited information, the condition of the lamina dura is a common and highly useful tool for radiographic diagnosis of periapical status. In a study of the influence of eighteen radiographic features on reliability and consistency of interpretation, Kaffee and Gratt[18] found that the lamina dura and PDL space were the features interpreted more consistently than all others, and that diagnoses based on these features were more accurate than the overall image diagnosis. The PDL and socket wall are the first periradicular structures affected by pulpal disease irritants, and the researchers determined the most reliable features in diagnosing pathologic changes in nonvital teeth were the shape and width of the PDL space and the continuity and overall imaging of the lamina dura. In none of the nonvital specimens was the lamina dura continuity or PDL shape and width interpreted as healthy.

## BONE LESION STUDIES

Given the importance of lamina dura interpretation in periapical evaluation, the significance of understanding the radiographic features of normal and abnormal bone is easily grasped. Many studies have focused on

the visualization of normal osseous architecture and the qualitative and quantitative changes associated with pathological lesions. It is ironic that a good portion of research devoted to advancing radiographic capability was incited by landmark studies focusing on the limitations of diagnostic radiography. These investigators took to heart the theme that would later be expressed by Prichard: "The value of the roentgenographic examination is not diminished by a critical appraisal of its limitations; the information it furnishes is essential and can be obtained from no other source. However, if roentgenograms are to be used intelligently, their limitations, as well as their advantages, should be known."[19]

In 1942 Borak[20] published his findings on the so-called "roentgen-negative stage" of bone metastatis. This referred to a triad of pain, microscopically present carcinoma, and a normal radiographic appearance of the affected bone, in this case spinal vertebrae. In postmortem examinations he found that even radiographs of thin sections of dried vertebrae revealed no metastatic lesions, even in the presence of abundant microscopic evidence of carcinoma. He attributed the roentgen-negative stage to the settling of bloodborne tumor cells in the spongy marrow's wide spaces, an area that produces an image shadow of much less density than that of compact bone.

In like manner, Shackman and Harrison[21] noted enormous discrepancies between antemortem x-ray reports and postmortem anatomical findings. They radiographed the debrided osseous tissue and found no evidence of disease. They found it reasonable to conclude that clinical radiographs taken at a greater distance from the bone and through the

superimposed soft tissue would be even less likely to reveal secondary sites of malignancy. Because of this, they issued a warning that any judgment about absence of bony metastasis is ill-advised and unjustified if based solely on a negative radiographic survey. They believed that extensive metastases to the skeletal tissues could be present without any demonstrable radiographic abnormality.

A 1951 report by Ardran[22] bolstered the arguments of his predecessors. He drilled vertical holes 3-14 millimeters in diameter through the center of two normal vertebrae. Radiographs gave clear evidence of these lesions if the specimens were dry, but virtually no evidence if the artificial lesions were filled with water, which has a similar density as normal tissue. The large defects, representing up to 30 percent of bone thickness, were easily misinterpreted as mild porosis only. He warned that secondary neoplasms or inflammatory bone destruction could easily be missed in routine radiography using conventional film techniques.

The significance of these studies was not lost on the dental community and led ten years later to the publication of an oft-quoted pair of articles by Bender and Seltzer.[1,2] Their purpose was to determine what conditions of bone destruction were not detectable by conventional oral radiographic techniques. As an example of their concern, they noted that if the lamina dura could somehow be obliterated from a recent extraction site there would be no obvious radiographic evidence of that significant cavity.

In their research, Bender and Seltzer[1,2] created artificial lesions in wet and dry mandibular block sections by using diamonds, reamers, files and burs.

Radiographs were made of these sections. In cortical bone, lesions less than one millimeter deep were not visible, but as the depth of bur penetration increased, so did the film density. The depth of the cut was a more significant factor than the bur diameter. In contrast, even with bulk removal of cancellous bone, no changes were noted in the radiographic trabecular pattern unless there was encroachment by the bur onto the inner cortical wall. They inferred that the trabecular pattern originates at the junction of the cortex and cancellous bone. They also stated that the alveolar bone proper appeared radiographically dense because of its relatively smaller content of fibrillar matter and larger amount of calcium-salt-rich cementing substance. Their judgment was that a lesion would only be seen if there were perforation or extensive erosion of the outer or inner cortical wall.

By surveying the normal position of each tooth in the mandibular arch, Bender and Seltzer shed light on the likelihood of early cortical erosion in periapical disease. The anterior teeth, bicuspids, and mesial roots of first molars are routinely in or near the buccal plate. The remaining roots in the arch are either embedded in cancellous bone or lodged in the lingual plate. They agreed with Borak[20] that inflammatory cells replace marrow cells first, and are thus undetectable on x-ray film. As PDL inflammation progresses at the expense of the lamina dura, it will eventually result in rarefaction as the cortex is eroded. In a first molar, only the mesial root may display signs of disease, even though both apices are inflamed.

Ramaden and Mitchell,[23] and soon thereafter, Pauls and Trott[24] validated much of Bender and Selter's work in the early 1960s. Removal of central

cancellous bone alone, or in the case of maxillary specimens removing central and (buccal) junctional trabeculae did not alter the image pattern. Trabecular images changed only if the cancellous-cortical junction was eroded.

Also bolstering Bender and Selter's conclusions was a study by Regan and Mitchell.[25] Instead of radiographing experimental lesions, they studied actual pathological conditions found in cadavers. In the fifty-seven cadavers examined, eighteen radiolucencies were found, fourteen of which had perforated the cortical plate. They found what is now commonly known, that the perforation is always of a smaller diameter than the deeper cancellous lesion. Thirteen of the fourteen perforating lesions were through the buccal cortex, a fact which should compel the clinician, Regan and Mitchell implied, to aspirate the lesions as a further tool of diagnosis.

Schwartz and Foster[26] also created experimental defects in dried mandibles to simulate various lesion types in bone and compare them with photographs taken before lesion preparation. These lesions included large bur holes through the base of a molar tooth socket, an antral-oral communication through a maxillary molar socket, a three-walled bony defect in interradicular bone, and complete removal of central cancellous bone. In none of these specimens was there diagnostically significant change in the post-lesion radiograph. An increased film density at the defect site was noted, but only when viewed adjacent to an unaltered area.

An excellent summary of this line of reasoning appeared in a study by van der Stelt[27] using long bone sections rather than jaws. He explained that these specimens were easily found, displayed less variation over distance, and

allowed study without interference from adjacent structures such as the zygoma or root apices. He carefully explained that the oft-noted junctional area is a region in which small marrow cavities are visible on a cross-section of bone immediately adjacent to the denser cortex, which does not contain medullary cavities. His results showed that, first, the removal of cancellous bone did not influence the radiographic image in a visible way, that damage to the junction changed the trabecular pattern but did not produce a radiolucency, and that sufficient outer cortical damage produced a radiolucency but did not alter the trabecular pattern. He theorized that bone loss became visible because it exceeded a threshold difference in the amount of radiation-absorbing material in adjacent areas. Only cortical bone had enough material per unit volume, so the threshold was exceeded. Trabeculae in the cancellous bone did not have enough material. Thus trabecular patterns must originate in the junctional area due to its more massive and voluminous trabeculae. A change in the trabecular pattern implied an extension of the lesion into the boundary between cortical and medullary bone.

Yet there were dissenting voices to the cortical erosion theory. In 1974 Shoha, Dowson and Richards[28] claimed that previous researchers had not controlled all experimental variables. By fixing specimen position, film placement, radiation source position and exposure/processing techniques, they hoped to remove all variation except bone loss. After removing the buccal or lingual plate, they created simulated osseous lesions around the apices of premolars and second molars. Serial films were exposed as the lesions were gradually enlarged until radiographically visible. They confirmed that the size of

the osseous lesions are always greater than their radiographic images, but they noted in the premolar region that the lesions were evident before the cortical-cancellous junction or cortical plate was involved.

LeQuire and associates[29] also attempted to standardize image acquisition in their study of experimental osseous lesions. They found that in 78-95PERCENT of cases, lesions involving only cancellous bone were detectable when film comparison was allowed. They suggested beam quality, higher amperage and voltage, and proper developing techniques as possible influences on visibility.

Pitt-Ford[30] performed endodontic therapy on 26 teeth in each of 6 one-year-old dogs, then compared radiologic and histologic status at 3 and 12 months postoperatively. Of those jaw sections available for examination, there was no evidence of cortical thinning. He found that these two examination techniques showed higher agreement in detection of disease than in determination of normal tissue. If a lesion were detected radiographically, histological lesions were found 85 percent of the time; if no radiographic lesions were evident, the tissue was histologically normal only 58 percent of the time. Pitt-Ford concluded that loss or thinning of the cortex was not a prerequisite for radiographic lesion presence.

Lee and Messer[3] also concluded that cortical involvement was not a necessary condition for radiographic identification of periapical lesions. They conducted research using 17 mandibular segments in which teeth were extracted and cuts were made to allow access to apical bone. The lamina dura and surrounding trabecular bone was removed several millimeters up the root

from each apex, and in some specimens a slurry of powdered rat bone was smeared around the lesion wall. Radiographs were exposed before and after lesion creation. The specimens were sectioned through the apices and further bucco-lingual films were exposed to verify non-involvement of the cortices. In 13 of the 15 specimens without intentional cortical involvement, the radiographically visible lesions were confined to trabecular bone. The remaining two involved junctional trabeculae but not the cortex itself. Lee and Messer attributed these results to four factors: 1) the radiopaque apex and adjacent structures as definite reference points for lesion location, 2) the creation of halo lesions extending up the side of the roots (rather than only apical to them), 3) the addition of a simulated sclerotic border and 4) removal of much trabecular bone so disturbances in its pattern would be seen.

## THE X-RAY BEAM

Throughout the last 100 years chance observations have led to scientific discoveries of vast importance. Probably the most commonly acknowledged serendipitous encounter was Sir Alexander Fleming's observations of the bacteria-inhibiting properties of simple mold, which led to the introduction of antibiotic therapy. On equal footing would be Wilhelm Conrad Röntgen's scrutiny of some fluorescing barium platinocyanide crystals and his subsequent description of what he termed x-rays.[31] When the general public caught sight of a photographic plate bearing the image of the bones of a hand, it ignited the interest of many future scientific researchers and clinicians.

What Röntgen had discovered was one of the invisible portions of the electromagnetic spectrum; that is, x-rays were one of the types of electromagnetic radiations. Radiation is the transmission of energy through space and matter; electromagnetic radiation moves through space as a combination of electric and magnetic fields. These fields fluctuate or oscillate in planes perpendicular to each other and are generated when the velocity of an electrically-charged particle is altered.[32,33] All types of electromagnetic radiation have the same general form and a constant speed, differing only in wavelength ($\lambda$), defined as the distance from one crest of the oscillating wave to the next. The number of crests or cycles per second is known as the frequency ($\nu$). The two variables are inversely related by the formula ($\lambda \times \nu = c$), where c equals the speed of light in a vacuum, or $3 \times 10^8$ meters per second. The unit of frequency is the Hertz, defined as one cycle per second.

These traits of electromagnetic radiation (EMR) are characteristics derived from the *wave theory* and account for many observations concerning light reflection, refraction, polarization, diffraction and interference patterns. For a more complete understanding of the nature of EMR, the *quantum theory* must also be highlighted. This presupposes that energy transfer by EMR is not through wave action but through discrete energy bundles known as quanta or photons. These photons travel at the speed of light and carry defined units of energy quantified by the electron volt (eV). Photon energy is related to wavelength by the equation $E = hc/\lambda$, where E is energy is kiloelectron volts (keV), and h is Planck's constant ($6.25 \times 10^{34}$ joule-seconds). This formula may

be simplified to $E = 1.24/\lambda$. The quantum theory has been very useful in describing radiation-atom interactions.[32]

The other form of radiation, equally important in the generation of x-rays, is particulate radiation. This consists of high velocity subatomic particles or atomic nuclei. One form of particulate radiation is the beta ray, which is simply a high speed electron. When discharged from a mechanical device, the beta ray is called a cathode ray and travels at about half the speed of light.[32] It is the cathode ray which when suddenly decelerated generates the electromagnetic radiation emitted from an x-ray tube.

The x-ray tube, its power supply, the tube head, the support arm and the control panel are the main components of an x-ray machine. The x-ray tube itself is air-evacuated and envelops the cathode and anode. The cathode contains a tungsten filament that functions as the electron source. The anode consists of a small tungsten target embedded in a copper sheath. The copper functions to dissipate heat from the tungsten, which has low thermal conductivity. When electrical current is applied to the cathode, an electron cloud forms outside the filament. A rheostat controls the amount of applied electricity, which in turn determines the size of the electron cloud or number of electrons. When a high-voltage circuit is applied, these electrons are repelled from the cathode and directed by a negatively charged molybdenum focusing cup across the gap toward the tungsten anode focal spot. The speed of their travel is determined by the potential difference between the two electrodes, which is controlled by the kilovolt peak selected on the control panel.[34,35]

Voltage refers to electric pressure or force. An alternating current travels in one direction, building from zero to peak potential, and then reverses direction, passing through zero on its way to its inverse peak potential. The sine wave generated by graphing this current is defined in part by the wave crests above and below zero. These crests are the kilovolt peak (kVp).[35]

The quantity of electrons accelerated toward the anode is measured by the milliampere (0.001 ampere or mA). Milliampere control modulates the emission of electrons from the filament. Increases in filament temperature bring about a corresponding increase in electron emission.[35]

Within the electrically grounded tube head and adjacent to the glass x-ray tube lies the unit power supply. It has two main functions. By means of a step-down transformer it must provide current for heating the electron-emitting filament. It also must generate the potential difference between the cathode and anode by employing a high-voltage transformer.[32]

The filament current control, or mA switch, regulates the step-down transformer, which reduces the incoming alternating current to approximately 10 volts. The mA switch modulates current flow through the low-voltage circuit and thus filament temperature. This in turn affects the number of discharged electrons, also known as the tube current. The tube current is measured by an ammeter.[32]

The energy needed to accelerate the electrons is provided by the high-voltage transformer, which increases the line current to 60-100 kV. Because that line current oscillates at 60 cycles per second, electrons are directed toward the anode a corresponding 60 times per second. However, since

alternating current reverses direction for half of each cycle, these electron bursts only occur when the polarity of the tube coincides with a negative filament and positive anode. In one second, therefore, 60 pulses of electrons move toward the anode in bursts of 1/120 second each. Electrons must never be allowed to reverse direction, for the resultant energy transfer would cause the filament to melt, thus ruining the tube. Rectification is the process of converting alternating current to direct current, thus preventing this so-called inverse voltage. Almost all common dental x-ray tubes are self-rectified, an efficient means of limiting electron direction that does not require additional rectifying devices. One consequence of self-rectification is the necessity of limiting exposure factors (kV and mAs) to relatively low values to prevent overheating of the anode and the resultant electron emission toward the filament.[32,33,35,36]

One design feature of the x-ray tube that increases operating efficiency as well as ultimate image quality concerns the angle of the focal spot (the tungsten target). The sharpness of the image varies inversely with the size of the focal spot. However, decreasing the size of the target increases the amount of heat generated per unit area. By inclining the target about 20°, the size of the target may stay relatively large compared to the effective focal spot size.[32]

Many modifications can be made to the x-ray beam, depending on the particular needs of the viewer. These include alterations in the operation of the tube (mA, kVp, exposure time) as well as manipulations of the beam itself (filtration, collimation, target-patient distance).[32]

Ideally, the amount of radiation emitted from an x-ray tube is directly proportional to the tube current multiplied by the operating time. A tube

operated at 15 mA for 1 second would release the same amount of radiation if set at 7.5 mA for 2 seconds. If the exposure time is doubled, the number of photons increases two-fold, but their range of energies remains constant.[32]

Increases in kVp lead to increases in the number of photons generated, and both mean and maximum photon energy. This elevated photon energy bestows increased penetration power to the photons. Only those photons which can effectively penetrate anatomic structures are of use in diagnostic radiology. Low energy photons will be absorbed by surface tissues, increasing the patient's exposure dose without improving diagnostic information.[32]

Filtration is the removal of longer wavelength x-rays from the beam. This is done by directing the beam through aluminum disks that prevent the low energy photons from passing. Inherent filtration includes the glass of the x-ray tube and its surrounding oil, plus any other structure located along the path from the focal spot to the edge of the tube enclosure. Total filtration is the sum of the inherent filtration plus any aluminum disks resting over the port of beam exit. The average photon energy of a filtered beam is higher than that of its original unfiltered state.[35]

An x-ray beam cannot be focused like a beam of visible light, but it can be shaped to a desired size by passing it through a lead diaphragm. This shaping, or collimation, reduces the size of the beam, thereby reducing the patient's exposure and increasing the ultimate film quality. In place of or in addition to a lead diaphragm, some x-ray units make use of tubular collimators or cones. Due to the angle of impact, a thin metal cone can present as much absorbing capacity as a thicker lead diaphragm. The image quality

improvement is a function of a decrease in scatter radiation. Many of the photons absorbed by the target tissue do not continue in their original trajectory. If they reach the film, they cause image degradation by addition of fog and uniform film exposure. Collimation reduces the volume of tissue from which this so-called Compton scattering originates.[32,35]

X-ray beam intensity is dependent on the distance from the focal spot to the film or receptor. The beam loses intensity as it spreads out while moving away from its source. The inverse square law is a relatively simple mathematical formula to determine new control settings if changes are made in source-object distance. The radiation intensity at a set distance from the radiation source is inversely proportional to the square of the source-object distance. If the length of the cone, for instance, is doubled and mA and kVp remain constant, the exposure time will need to be quadrupled to expose the target tissue to the same quantity of radiation.[36]

The exposure parameters just described will individually and collectively influence the final radiographic image. The most common qualities used to describe that image are density, contrast, and resolution. Density refers to the overall degree of darkness of the image. Contrast concerns the density difference between various segments of the image. Resolution refers to the ability to discern closely adjacent fine structures.

Density is dependent upon the total number of photons striking the sensor or film, thus any exposure factors that increase the photon quantity will increase film density. Therefore, increased mA, kVp, or time will darken the

Low contrast images have many more gray shades and are often called long grayscale images. The primary x-ray beam determinant of image contrast is kVp. When comparing, for example, a beam of 70 kVp versus one at 90 kVp, the latter will have more photons of higher energies than the former. More energy levels lead to a higher number of gray levels. The relative merits of high and low kVp techniques have been debated.[37-39] General agreement exists that the optimal kilovoltage and exposure time should be individualized for each x-ray unit and clinical requirement.[40]

Resolution and image sharpness are unrelated to adjustable factors of beam quality. They are related to movement during x-ray exposure, image receptor quality and focal spot size. The latter is a built-in feature of the x-ray tube and cannot be adjusted.

## CHARGE-COUPLED DEVICES

In 1970 Boyle and Smith[41] of Bell System Laboratories introduced the charge-coupled device (CCD), a landmark development in the field of digital optics and imaging that stemmed from 1960s research on photodiodes. CCDs for commercial applications did not start until the '70s and '80s, being incorporated into a variety of electronic devices such as telescopes, microscopes, gastroscopes, videocameras, and more recently, radiographic imaging systems.[8] The CCD functions as the image receptor or sensor, in a wide variety of imaging equipment.

Charge-coupled devices allow the collection, organization and display of light or x-ray photons by first converting them to electrical charge. This

functions as the image receptor or sensor in a wide variety of imaging equipment.

Charge-coupled devices allow the collection, organization and display of light or x-ray photons by first converting them to electrical charge. This conversion is initially dependent upon the interaction of electromagnetic energy with the element silicon. When in crystalline form, silicon atoms are bonded covalently to each other, forming a three-dimensional lattice. Roughly 1.1 Volt is required to break one bond, resulting in an electron-hole pair. Thousands of bonds can be broken by electromagnetic radiation if the wavelength of the incident photons is shorter than $1 \times 10^{-6}$ meters.[42]

Charge coupling itself is the process of sequentially transferring the accumulated photons from one electron well to the next and eventually to a read-out amplifier.[8] These electron wells, also known as potential wells, are made from thin layers of silicon dioxide grown on a wafer of silicon. A conductive gate structure is applied to the oxide surface.[42] By applying a positive potential to the gate, a depletion region is formed, serving as a storage area for the free electrons generated by the incoming photons. It is possible to organize a set of these independent potential wells into a series of rows and columns known as a parallel register. Each well is commonly called a pixel (picture element). An image focused on the parallel register will produce a charge pattern proportional to the number of electrons captured by each pixel.[8] Row by row, the charge information (or charge packet) is shifted toward the serial output register. Each packet is individually transferred to the output amplifier for conversion to a signal that is proportional to the charge quantity of

the packet. When all charge packets in the row have been converted, the next row is shifted into the serial register. This process continues until all charge information has been sent to the output amplifier. The array is then ready for a new exposure.[42,43]

Although basic CCD design is established, modifications have been attempted to improve or adapt the CCD to a particular function. When used as an intraoral radiographic sensor, two paths of construction have been taken to overcome a certain property of the thin polysilicon gates. At long wavelengths these gates are relatively transparent, but for wavelengths shorter than 400 nm, which includes x-rays, the gates tend to become opaque. By thinning the CCD with an acid etching process to about 10 μm in diameter, an image can be focused on the opposite side of the array, avoiding the gate structure. Another method is to place an image intensifier between the radiation source and the CCD array. These are x-ray-sensitive phosphors that convert incoming x-rays to a wavelength within the visible spectrum that matches the peak detector response.[44] These lower energy photons are focused on the parallel register by means of either a series of optical lenses or a fiber optic bundle.[42] The latter structure is composed of strands of glass fiber stacked and fused into a rigid and coherent optical transmitter. This element is then carefully bonded to the CCD array in order to translate the image plane to the fiber optic bundle surface.

From intraoral and panoramic radiography to quantitative optical microscopy[45] to upper GI and chest radiography,[46] CCD technology has been adopted for a variety of medical uses. The specific performance characteristics

of the array may vary due to the unit's construction design as well as the use for which it is intended. Although comparisons of specific imaging systems will be made later, a general description of CCD attributes is in order.

The ability to distinguish between small objects positioned close to one another is termed resolution.[8] The pixel is the resolution element of the CCD, and the size and shape of the pixels are the primary determinants of the unit's resolving power. Pixels are routinely square, both to avoid dead space and to maintain symmetrical spatial image sampling. The charge transfer efficiency (CTE) also affects resolution. Although done in microseconds, the passing of charge packets from the parallel array to the output amplifier entails thousands of discreet transfers. Reports of CTEs as high as 0.999998 have been recorded in the literature.[42]

In imaging science, resolution is commonly quantified by how many line pairs per millimeter (lp/mm) may be resolved. Although standard dental film has a resolving power of about 16 lp/mm and current CCD technology allows resolution of 9-10 lp/mm, both systems are sufficient for unaided human vision, which has resolving capacity of only 4-6 lp/mm.[8]

The ideal relationship between incoming radiation and the output signal should be one of exact linearity, in which a plot of the light levels versus the digital numbers representing those levels is a straight line.[42] Scientific grade CCDs have excellent linearity (to within a few hundredths of one percent). This is essential, because nonlinearity in digital processing can introduce significant error and erroneous interpretation of imaging data. Linearity is often known as photometric accuracy.

Electronic noise consists of unwanted signal components arising from each element of an electrical system. The more noise inherent in a system, the harder to discern fine detail or low contrast areas within an image. Current CCD technology provides for a very high signal-to-noise ratio (SNR).

X-ray sensitivity is not as easily quantified as signal-to-noise ratio, but is basically a measure of the minimum detectable signal of the receptor. This is mainly determined by two factors. The first is the system noise level, mentioned above. The second is the quantum efficiency of the CCD, which measures the sensor's efficiency in electronic charge generation when exposed to incident photons.[42] Current intraoral CCD sensors have much higher sensitivity than conventional film.

The dynamic range is synonymous with exposure latitude of conventional film.[8] In electronic imaging, it is the ratio of the device's saturation charge to the system noise level.[42] Saturation charge is limited by the potential wells' electron capacity, which varies with pixel size and architecture. CCD's have wide dynamic range, which is also related to the device's linearity.

## DIRECT DIGITAL IMAGING

As categorized by Gröndahl[47], the purposes of a radiographic diagnosis include establishing the presence or extent of disease suspected from the clinical evaluation; screening for disease in normal patient populations; monitoring disease and treatment effects; and choosing treatment alternatives with the best long-term prognoses. With these criteria in mind, a basic question must be answered: will any new imaging system bring sufficient benefit to

justify replacement of conventional film? The bulk of research exploring the nature and potential of direct digital imaging has been directed toward answering this question.

Direct digital imaging commonly refers to the process of recording an original image on a non-film receptor. In contrast to film-based methods in which the film serves as the detector, storage medium and display mechanism, film-free methods rely on three separate devices for those functions. The first apparatus, the CCD detector has already been discussed. Once the charge sequence has been transferred through the serial register to the output amplifier, the signal is sent to the central processing unit of a computer, the second link in the chain. The computer contains an analog-to-digital converter and frame storage capacity. The digitization of the CCD readout produces a mosaic pattern grayscale image which can be printed on thermal paper[48] or displayed on a video screen.

It is generally accepted, as noted by Dunn and Kantor[49], that digital receptors cannot yet equal the information content of standard film when unaltered images are directly compared. It is the potential for manipulation of the digital information that makes it so appealing. While both systems may show improvements in image recording as research progresses, only digital imaging has much latitude in optimizing the display of information.[50] That latitude stems from the nature of digitization, which is a precise mathematical exercise, ideally suited to computer analysis and modification. The pixel values from the CCD array are analog values converted to digital numbers by the central processor. These numbers are expressed as a series of 1s and 0s,

each of which is termed a bit. A 1 represents a timed pulse of electricity, while a 0 represents a timed lack of pulse.[51] The number of bits per pixel is directly correlated with the precision of the image representation. If only one bit were used for each pixel, then the image would be made up of an array of black or white squares. However, if 4 bits were available there would be 16 gray levels available for each pixel. The number of gray levels is determined by raising 2 to the power equal to the number of bits available (e.g. 4 bits--$2^4$--sixteen gray levels; 8 bits, which equals 1 byte--$2^8$--256 gray levels).[52] Higher pixel bit-lengths correspond to increased detail of the image but also increased storage requirements and transmission and processing time.[53]

As stated, digital images are altered mathematically, thus any number of transformations are possible if the correct formulas are used. These transformations are useful in removing blur, smoothing out graininess or noise, improving contrast or other visual characteristics, magnifying and segmenting the image, removing distortions, or coding for electronic transmission.[54] Moreover, the original image need not be lost. By using look-up tables (LUTs) the images are not changed during processing, but can be efficiently translated on the way to display.

Frost and Staab[55] reviewed the display technology on which these processed images are seen. The cathode ray tube (CRT) is now, and for at least the near future will be the dominant display tool available for common use. Within a CRT, the output image is formed by an electron beam scanning a phosphor screen. The beam's intensity is modulated according to the two-dimensional density pattern of the image to be reproduced. The screen

phosphors are composed of several layers of 5-10 μm thick particles, and they deliver a peak resolution greater than 40 lp/mm. The size of the electron beam is a limiting factor in monochrome displays, however, their resolution is more precise than that of color units. The deficiency of color displays is often overcome by the human ability to detect subtle color change much more keenly than intensity (monochrome value) change, as will be discussed later.

Currently available CRT technology demands tradeoffs among brightness, spatial resolution, contrast, geometric distortion, unit size and weight, color capability, brightness and cost. Frost and Staab call for efforts to determine the minimal display performance requirements necessary for accurate clinical diagnoses.

One obvious difference between viewing an intraoral film and a CRT display is the size of the image. Moystad and associates[56] compared the diagnostic accuracy of intraoral dental films with corresponding unprocessed digital images displayed on three CRT's with similar resolution but different image size. Seven experienced and 12 inexperienced observers evaluated 85 artificially prepared lesions in dry mandibles. Their results suggested that images displayed on the smaller (5 and 9 inch) screens were not statistically different from conventional radiographs, while the larger screen (17 inch) led to significantly inferior results. No improvement was seen when comparing experienced evaluators to inexperienced.

Wenzel[57] evaluated whether varying the grayscale levels (the number of bits per pixel) would affect observer diagnostic accuracy of bone lesion detection. In a series of digitized films displayed with a 512x512 spatial

resolution on a 14-inch monitor, she found that original radiographs were never better than 8-bit resolution, and that even 64 gray levels (6-bit) provided diagnoses as valid as the conventional films. There was diminished diagnostic accuracy with 32 gray levels.

In an effort to describe the difference between an analog and digital image, Farman and Scarfe[51] compared the continuously variable brush strokes of oil and canvas with the numerous discreet dots of pointillism, a late 19th century painting style. From a distance (poor resolution) the two paintings may be indistinguishable, but when viewed closely, the smoothly textured analog image remains intact. The digital image looses its cohesion. The visual appeal of the digital image is related to the fineness of the mosaic matrix.[52] The smaller the pixel size, the greater the spatial detail discernible.

McMahon and associates[58] used the subtle radiographic changes of pulmonary interstitial infiltration and pneumothorax to compare conventional and digital radiography, and within the latter technique to compare four pixel sizes for diagnostic accuracy. Within the confines of the study, 0.1 mm pixels were significantly better than 0.2, 0.5, and 1.0 mm pixels in improving diagnostic accuracy. The authors concluded that for a given application optimal pixel size will be just small enough to yield an acceptable level of diagnostic accuracy. By not demanding more spatial resolution than necessary for a particular task, savings can be generated both in cost of equipment and data storage requirements.

Giger and Doi[59] investigated the relationship of pixel size to signal-to-noise ratio and to threshold contrast, the latter being the contrast required for

detection of an object or pattern. They found no substantial difference between 0.1 and 0.2 mm pixel sizes in the detection of square objects ranging in size from 0.1 to 20 mm. For pixels of 0.5 mm or greater, much higher threshold contrasts were required to detect small objects. They offered these dimensions as guidelines for further research, stating that specific diagnostic procedures might require greater or lesser resolution.

Indeed, digital imaging in general is task specific[49] and not equally useful in all disciplines. As said earlier, digital imaging does not increase information content but can alter the relevant weight of information appropriate to the task at hand. Quantitative measurement is greatly simplified, but though precision may increase, accuracy may not necessarily improve.

Wenzel and associates[60,61] studied the ability of digital imaging methods to aid in the estimation of occlusal caries depth, then compared these estimates to actual histological measurements. Overall, digital image processing led to much greater accuracy than standard film or direct visualization. Even when displaying small approximal enamel lesions, digital imaging performed as well or better than conventional radiography.

Periodontal diagnosis and therapy is enhanced with direct digital imaging. By exploiting the quantitative information available about, say, bone deposition or loss in a periodontal defect, observer subjectivity might be reduced.[62] Digital subtraction radiography, although predated by photographic subtraction, eliminates most of the latter method's labor intensiveness.[49] By reproducing alignment and angulation of serial films, subtle density changes occurring over months or years can be highlighted and analyzed. Qualitative

analysis may be done visually with a monitor display; quantitative analysis may be done by mathematical measurement of density variation.[63]

Research is also underway in extraoral direct digital imaging. McDavid and associates[64] ran a pilot study in which cephalometric, anterio-posterior and Water's images were made of dry skull specimens. They used a direct digital scanning slit prototype machine, the slit beam used for the elimination of scatter radiation. Their results suggested the spatial resolution obtained might be adequate for cephalometric analyses and most diagnostic tasks.

## DIGITAL IMAGING SYSTEMS

The challenge of packaging CCD technology into usable clinical systems has been taken up by a handful of corporate competitors. The first system ready for clinical use was RadioVisioGraphy (Trophy Radiology, Marietta, Ga.), introduced in 1989. In their initial presentation, Mouyen and associates[65] cited the two major disadvantages of conventional film, in their words a "fairly high" radiation dose and interruption of treatment while film processing is accomplished. They cited RadioVisioGraphy's ability to overcome these deficiencies by producing an almost instantaneous image after exposure and at a lower dose.

The acronymic term RadioVisioGraphy (RVG) highlights the three basic components of the system. "Radio" refers to a conventional x-ray generator connected to a microprocessor timer and the associated intraoral CCD sensor. "Visio" represents the signal storage and conversion attributes of the system.

"Graphy" alludes to the mass storage unit connected to a display monitor or video printout device.

Since its introduction, many studies have been completed to evaluate the clinical attributes and overall utility of the RVG system. Most have highlighted the positive qualities of filmless radiography: instant viewing, contrast control, magnification, gray level and color enhancements, reduced radiation load to the patient, computer storage and transmission[66], and medico-legal documentation.[7] Others have focused on key features of the system. Soh, Loh and Chong[67] used thermoluminescent dosimetry to compare radiation dose levels in sample periapical radiographs using RVG and Ektaspeed dental film (Kodak, Rochester, N.Y.). RVG doses averaged only 22.3 percent of that required for the conventional film. Kircos and associates[68] determined that RVG images were much less noisy than conventional film but had less resolution. However, Benz and Mouyen[69] noted a 46 percent increase in sensitivity from the second to the third generation RVG system. They reported a 7 line pairs/mm resolution capacity in standard setting and 11 line pairs/mm in zoom high resolution setting. Also noteworthy was their statement that RVG had the highest resolving power of any commercially available digital radiography processors, including those used for computed tomography and digital subtraction angiography.

Chen and Hollander[70] evaluated RVG exposure control and detector response to radiation. They found the timer precision to be high, with a reproducibility range of 0.02-0.12 seconds. Even so, there was some lack of

accuracy in the timers. By comparing two receptor samples, they found a statistically insignificant difference in response to different exposure settings. Both sensors had lower pixel values in the center areas than at the periphery, indicating an inhomogenous detector response.

Nowhere has interest in the RVG system been keener than in the field of endodontics. Shearer, Horner and Wilson[71] found no statistically significant difference between RVG and conventional radiography in the percentage of root canal length visible in a sample of 60 extracted teeth. However, they noted that by using the built-in enhancement features it was possible to clarify existing information about canal presence and characteristics. The same authors[72] placed size 15 Hedström files in extracted teeth and evaluated length estimation in root canal treatment. They found conventional film demonstrated about 2 percent greater file length visibility than did RVG, but by enhancing the digital image to increase contrast, the statistical significance of this difference was eliminated. They found RVG an acceptable substitute for film-based file length determination, but they recommended use of enhancement functions to maximize the RVG image.

Leddy[73] found no significant difference between RVG and conventional film in the ability of endodontists to make accurate file length adjustments.

Yokota[74] compared film and RVG systems in demonstrating simulated periapical lesions. He found that in "early" lesions, those involving lamina dura and medullary bone, RVG was diagnostically superior. When no lesion existed, conventional films were more diagnostic. When lesions were destructive enough to involve the cortical plate, no difference was noted between systems.

Tirrell[4] used perchloric acid to simulate periapical lesions. His results suggested that RVG had the capacity to demonstrate radiographic changes in cortical bone, secondary to osseous demineralization, at an earlier point than conventional radiography.

The RVG sensor is of the scintillation screen/fiberoptically-coupled design, in which x-rays cause phosphorescence of the screen in the visible light spectrum. These light photons are transferred via prismatic optical fibers to the surface of the CCD. In contrast to this design, the Sens-A-Ray system (Regam Medical Systems AB, Sundsvall, Sweden) was the first with a CCD detector designed for direct conversion of x-ray energy to electronic signal.[75] The Sens-A-Ray sensor is radiation hardened. Its detector package is much thinner than those using an intensifying screen or conventional optics. Nelvig and associates[76] found this sensor provided images of adequate diagnostic quality at one-half to one-third the exposure required by E-speed film. McDonnell and Price[77] compared the unit to D- and E-speed film. When comparing resolving capacity, the line-pair images used in the evaluation were not as clear with the Sens-A-Ray device, but all systems could resolve 10 line pairs/mm, which is beyond the ability of unaided vision.

As more systems enter the dental marketplace, more studies are comparing them to each other and also to conventional intraoral film. In an acknowledgment of the complexity of this task, Wenzel[78] took a novel approach to evaluating the somewhat obscure topic of sensor noise. Noise is inevitable when using electrical systems, but as mentioned previously a high signal-to-noise ratio minimizes image distortion and reading error. Wenzel proposed a

simple test to evaluate random noise: recording two identical exposures and then digitally subtracting one from the other. The homogeneity of the subtracted image would be an expression of system noise. The homogeneity was evaluated by studying the standard deviation of the image histogram; the more shades of gray in the histogram, the more noise in the subtracted image, therefore, the larger the standard deviation. Multiple exposures were made at three different exposure times. Systematic digital subtraction was used to evaluate three systems: RVG, Sens-A-Ray, and Vixa/Visualix (Gendex Corporation, Milwaukee, Wis.), a new system using a radiation-hardened sensor similar to Sens-A-Ray. Vixa was determined to display the most noise, RVG the least. Both Vixa and Sens-A-Ray subtraction images had crown contours clearly visible. Wenzel summarized the significance of these findings by noting that to perceive fine tissue changes, system noise must be minimized. Sensor sensitivity must be balanced against system noise so the radiographic unit may achieve the lowest possible dose not adversely affecting the diagnostic outcome. In direct digital imaging, relatively low doses of x-radiation are needed to saturate the sensor. Any dose over this reduces the signal-to-noise ratio. Therefore, the practical risk of increasing sensor sensitivity is a corresponding reduction in signal-to-noise ratio.

Sanderink and associates[79] compared RVG, Visualix and Ektaspeed film in root canal length determination. Size #10 and #15 files were placed in the root canals of sample upper and lower premolars, both at full length and 1.5 mm short of the apex. RVG and Ektaspeed film were found to be equivalent in length determination; Visualix was found to be not as accurate. Ektaspeed film

led to slightly more accurate length estimation when a #10 file was used. With a #15 file, RVG and film were equivalent.

Scarfe, Farman and Kelly[80] reviewed the attributes of Flash Dent (Villa Sistem, Medicali, Buccinasco, Italy). This unit makes use of a rare earth intensifying screen to gather x-radiation and transfer the fluorescence to the CCD array. Rather than a fiberoptic pathway between screen and sensor, the Flash Dent system makes use of a set of seven optical lenses. The evaluators were critical of the "extremely narrow" exposure latitude compared with film, the variation in sensor responsiveness between the center and periphery, and the "bulky, hard to position" detector handle. The unit did display many desirable characteristics, but the authors believed further development was necessary "in regard to x-ray generator output, sensor performance and dimensions, and standardization of the image file format."

Sanderink and associates[81] expanded their previous root canal length study by comparing all imaging systems mentioned thus far to Ektaspeed film. They noted that except for the high-resolution setting of the Flash Dent unit, all systems required no more than 40 percent of the radiation dose needed for the conventional film. They also pointed out that the similar sensor dimensions of the units did not result in similar screen image size. Although no system varied from the others by more than 4 mm in sensor width or length, the image size on the monitor was directly related to the number and size of the pixels within the sensors, thus great variation was seen on the screen. The researchers concluded that when using a size #15 file for length determination, E-speed film was slightly better than the best digital sensors, and with a #10 file the film was

markedly better than all digital systems. The conventional film, RVG, and Sens-A-Ray units delivered statistically similar information.

## COLOR PERCEPTION

Color is unique because it cannot be confirmed by any tool or method other than vision.[82] Historically, the understanding of color physics preceded the understanding of color physiology. The development of color physics emerged from an understanding of the larger subject of light physics, which by itself arose over the span of many centuries. Even Greek philosophers understood that something must be transmitted between the eyes and an object in order for it to be perceived. In the tenth and eleventh centuries A.D. the Arabian Alhazen wrote of an optical image being produced in the eye, and 500 years later Leonardo da Vinci worked with the ideas of perspective and visual fields.[82] Johannes Kepler, known most commonly for his theoretical concepts in astronomy, was also intrigued by the perception of light. He proposed, correctly, that image receptors were located in the back of the eye.

Eventually, the first landmark research on the physical nature of light took place in the laboratory of Sir Isaac Newton. With painstaking detail he recorded his observations on the separation of white light, by means of glass prisms, into the visible light spectrum, consisting of red, orange, yellow, green, blue, indigo and violet. When Newton's *Opticks* was published in 1704 the prevailing worldview on the nature of light transmission was the medium or wave theory.[83] This idea bordered on the philosophical, since it demanded the presence of an undetectable and ethereal medium that filled all space and served to transmit

light waves from the object to the eye. Newton's brilliant research was a major force in the movement of optics from the philosophical realm into the domain of mathematics and science. Today it is well known that no medium is required to transmit electromagnetic radiation, including the spectrum of visible light that is found within wavelengths of 400-700 nanometers.[84]

In the early to mid-nineteenth century, the gap narrowed between the science of optics and the more nebulous realm of vision and perception, even as advances were made in both arenas. In attempting to comprehend the various spectral hues and the eye's ability to make sense of them, Thomas Young proposed a trichromatic theory of vision, theorizing that the relationship between wavelength and hue depends on three types of receptors in the retina, with overlapping spectral sensitivities.[82] Given the fact that retinal physiology was still in its infancy, this theory was keenly insightful. Herman von Helmholtz, the renowned German physician, validated many of Young's ideas in his work, *Physiological Optics.*[85,86] As research progressed, a modified theory of color was introduced by Ewald Hering in the early 1900s to account for some inconsistencies in the trichromatic theory.[82] This "opponent-color theory" or "opponent process," recognized that the three large bands in the visible spectrum--green, red, and blue--can combine to form all other colors but cannot themselves be produced by mixing other light colors.[84] In fact, these primary colors could be combined in such a way as to cancel each other out, in the sense of forming white light.

It soon became well understood that the primary colors "cannot fully describe what we see but refer to a theory of the color-vision mechanism that

draws heavily on the results of light mixtures."[87] Having apparently simplified the sensation of visible light into a workable system of primary color mixing, it soon became apparent that the visual system was infinitely complex. Today, color can be described in terms of set parameters--hue, value and chroma--but the perception of color is influenced by many things: the actual color of the perceived object, the color of light illuminating the object, light intensity, contrast effects, background illumination, afterimages, and even the location on the retina where the image is focused.[87]

Hue has been described as "that quality by which we distinguish one color family from another, as red from yellow, or green from blue...."[88] Value is an achromatic attribute of visible light and refers to the relative lightness or darkness of a color. White, black and intermediate grays would thus be described as hueless colors. They would be defined only in terms of value, which could be analogized to the axle of a wheel. Hue would be represented by the wheel's spokes. Chroma, the third dimension of this color wheel, refers to the "relative white content of a stimulus perceived as having a particular hue."[82] Chroma would describe the distance between the axle and a particular point on a spoke.

Within the retina are two types of light receptors. Rods are primarily involved with scototopic or night vision. This would, of course, correspond to an affinity for the value dimension of the color wheel. Cones are the primary receptors for photopic or daylight color vision. They sense the hue and chroma of a perceived object. Three types of cone pigments exist: erythrolabe (red), chlorolabe (green), and cyanolabe (blue). Boynton[1] thus summarized: "the

initial basis for color perception therefore lies, as Thomas Young suspected long ago, in the relative rates of light absorption by the three types of photopigments."

An interesting aspect of the physiology of the eye is that the fovea centralis, where spatial acuity is highest, light-adapted sensitivity the greatest, and attention value the highest, is devoid of rods and has the most densely packed cones of any portion of the retina. This leads to the conclusion that our best visual acuity is color dedicated. Simple verification of this can be found by observing a star field. When an observer looks directly at a faint star, it often disappears; when viewed with peripheral vision, the star reappears.

Only quite recently have methods been developed to take advantage of our full perceptive abilities, namely color imaging.

## COLOR IN MEDICAL IMAGING

In fields of science dedicated to the study of human disease, observation of pathological processes and their results is a key element in developing effective means of treatment and prevention. Until the development of radiological imaging, no noninvasive techniques existed to view internal anatomy. Those clinicians using radiographic images in their practices were quite familiar with their inherent limitations, i.e. the inability to visualize soft tissue, the monochrome display of information, and the inability to view active pathology if bone resorption had not begun.

With the passage of time, new tools were developed to probe the inner workings of the human body. While some involve the use of ionizing radiation,

others involve the use of high frequency sound waves and strong magnetic forces. None of these were possible without powerful computer assistance. Not only were new forms of imaging feasible, but previously unimagined methods of image manipulation became possible, a chief one among them being pseudocolor enhancement.

The term *pseudocolor* is a recognition of and a reminder that any color displayed on the image is not truly the color of the object under study. Rather it is an enhancement available either to add more information to the image or to allow easier discrimination of details within the image. It allows practical application of "the physiologic ability to discriminate color levels better than gray levels."[89]

One major line of investigation into the benefits of pseudocolor enhancement has been color-Doppler imaging (CDI). In the last 5-10 years applications of CDI have made inroads for the diagnosis and treatment of a wide variety of conditions, ranging from cerebral artery aneurysms to malignant ovarian masses. Kremkau[90] described CDI as:

> ...a technique in which two-dimensional real-time presentations of blood flow information are displayed for medical diagnostic purposes. The colors are given hues, saturations, and brightnesses to indicate presence, direction, speed, and type (laminar, disturbed, turbulent) of flow. This information is superimposed on the two-dimensional grayscale anatomic cross-sectional sonographic image.

The change in wavelength or sound frequency that results from the motion of the source or receiver is known as the Doppler effect. In the case of ultrasound imaging, the motion is that of the moving blood, and the frequency changes are dependent of the speed of flow, its relative direction, the speed of

sound and the frequency of the ultrasound wave. A standard, non-Doppler-shifted echo represents the anatomy of an area and is represented by a grayscale image. The Doppler-shifted echo thus represents the physiology. The superimposition of color to the normal grayscale image allows presentation of the direction, speed and character of blood flow.

Bluth and Merritt[91] reviewed the utility of CDI in imaging the extracranial carotid and vertebral arteries. They found this technique to be equivalent in accuracy to arteriography when used to evaluate flow-restricting stenosis. The high-resolution capabilities of the newer CDI systems were judged capable of properly characterizing intra-vascular plaques, as well as more rapid scanning of more challenging cases.

Pellerito and Taylor[92] noted that although contrast angiography is "still widely regarded as the gold standard for the assessment of vascular disease," CDI overcomes angiography's major deficiency, that being an inability to provide anything other than anatomic information which may be poorly related to the functional deficit. The authors consider CDI a major advance over angiography due to its noninvasiveness and easy repeatability. It allows effective evaluation for peripheral artery angioplasty, presurgical mapping of veins used for bypass grafts, and postsurgical study of graft patency. Although pitfalls remain, the authors contend that CDI may soon "supplant angiography as the primary imaging modality in peripheral arterial diagnosis, reserving arteriography for interventional procedures."

Schoning and associates[93] reported the first case of CDI used to map an intracerebral aneurysm. Real time CDI allowed determination of the size and

location of the lesion, and the "pulsating intra-aneurysmal flow" was clearly demonstrated in the patient, an 11-year-old boy with a giant fusiform aneurysm of the middle cerebral artery. The authors noted that the images were not comparable in quality to those of computed tomography or MRI, but in contrast to those techniques the images were easily obtained at bedside and did not require any radiation burden to the patient, no matter how many images were required.

Dougherty and associates[94] used color-flow ultrasonography in evaluating renal vascularization prior to surgical closure. In their study, color-flow imaging successfully revealed technical abnormalities that required operative revision to ensure adequate renal perfusion.

The ability to evaluate hemodynamics with the addition of pseudocolor to a sonographic image also pays dividends in distinguishing benign tumor masses in the ovaries from malignant ones. Spreafico, et al. [95] reported that CDI transvaginal examination allowed a high frequency of ovary visualization, small lesion definition, and visualization of small parenchymal vessels, whether physiologic or pathologic. Statistical analysis from their research showed sensitivity and specificity above 90 percent.

Recently, Miyagi and associates[96] reported development of a three-dimensional color-Doppler system. A pseudo-3D reconstruction of umbilical vessels and blood flow was formed, allowing for potentially improved prenatal evaluation.

Another highly valuable medical diagnostic tool is magnetic resonance (MR) imaging. These images are normally displayed using grayscale contrast,

thus allowing presentation of a single parameter of information. Alfano and associates[1] developed a technique, using the three primary colors, to allow the combination of "multiparametric MR information into a single color-coded image, where each MR parameter is displayed as a 'magnetic color' component of the image." They noted that the color images preserved all anatomic information, enhanced contrast, and provided the potential to detect small lesions more successfully.

## HISTOGRAM EQUALIZATION

A common radiographic image, when digitized to an 8-bit format, nicely corresponds to the standard organization of computer memory into bytes. One byte of storage will contain the brightness value from one pixel in the image.[97] An 8-bit number therefore allows $2^8$ or 256 levels of gray (0-255, black to white). In periapical radiography many areas are commonly found with high brightness values (enamel, dentin) and other areas with low values (soft tissue.) A common method of mapping these values is by means of a histogram, which may be thought of as a probability distribution for each gray level in the image. It is a relatively easy computer calculation to determine how many pixels are displaying a gray level of zero, of one, and every other value through 255. These totals are then plotted on a two-dimensional graph. In the case of a periapical x-ray, it is common to find a large peak of low value (soft tissue -- dark) and a similar peak of high value (enamel/dentin -- light). There is a relative scarcity of pixels in the mid-range of brightness values, and this will be displayed as a valley between the two peaks of the graph.

Niblack[54] stated that the most common method of contrast enhancement for an image such as this was histogram equalization. Originally developed in the early 1970s by Andrews and Hall[98], histogram equalization is, in a sense, a means of transferring some pixels away from the peaks and into the valleys. This permits a more equal distribution of gray levels throughout the histogram and image, thus allowing subtle density differences to stand out.[99] The pixels retain their brightness order, remaining brighter or darker than others, but the values are shifted, permitting a roughly equal number of pixels to display each possible brightness value.[97] It is one method of maximizing available information by changing pixel values to produce a more uniform density distribution,[100] which Hall[101] stated is ideal. This uniform allocation of gray levels enhances low detail information because of its inherent range compression. This change of contrast may allow the examiner to see minor variations in brightness that are nearly uniform in the original image.[97]

The utility of histogram analysis and modification is a relatively new question in dentistry. Verdonschot and associates[102] used five types of modification, including equalization, in an attempt to improve diagnostic accuracy in small proximal carious lesions. Wenzel, et al. [103] compared various tools in the detection of non-cavitated occlusal caries, including fiberoptic transillumination and a derivative histogram modification. Interestingly, at the threshold of early penetration of dentinal caries, the fiberoptic technique was significantly better than all radiographic analyses, conventional or digital. However, at the threshold of deep dentinal involvement, no statistically significant difference was noted.

Although it is a relatively unused technique in conventional dental imaging, histogram equalization has been used in certain medical disciplines for many years. Engh and associates[104] used this technique to compensate for the varying film quality of serial radiographs of femoral prostheses. By digitizing and equalizing the images, a baseline "fingerprint" could be recorded, to which all future images could be compared. Since film exposure can be greatly affected by minor differences in energy (kVp), contrast can be quite variable among films. Equalizing each image produced histograms that could then be adjusted to a known constant, in this case the metal prosthesis (brightness value 255). Areas of bone remodeling could then be found and evaluated more easily, because portions of the sequential histograms would not match from year to year.

It is well established[97,98] that "global" histogram equalization, in which all pixels in the image are equalized en masse, may not always be necessary or desirable. One weakness of a simple equalization approach is its assignment of gray values based on the area covered by the various image features rather than the relative importance of those features.[105] This deficiency is compounded by the almost universal understanding that radiologists and other specialists in visual interpretation do not focus for long on the entire image, but rather examine various regions of the whole in a systematic manner. Pizer, Zimmerman and Staab[105] acknowledged that this technique may needlessly sacrifice small feature contrast in the digital reconstruction of the whole image.

In efforts to address the drawbacks of "global" histogram equalization, much research has been focused on "regional" or "adaptive" histogram

equalization, in which a digitized image is broken into several regions, each of which is equalized prior to reassembly of the whole image. Certain limits must be acknowledged. If too big a block of information is presented, nothing may be gained through equalization. If too small a block is available, there may not be enough information to compute and correct the histogram. For instance, to allow the use of all 256 gray levels, the pixel block must contain at least 256 pixels (16 X 16). Another limitation, as Analoui[100] stated, is one of computational demands. To remove the artifactual boundary line that inevitably results between equalized regions, overlap of these regions is required. The more overlap desired, the more computation time is needed.

This adaptive histogram equalization has so far shown limited but often promising results. Verellen and associates[106] tested several digital enhancement techniques used to improve image quality of pelvic field radiology. In a comparison with non-enhanced images, a panel of radiation oncologists and radiotherapy technologists found the technique to improve low-contrast images but degrade good quality images. A followup study by Rosenman, et al.[107] added a pre-equalization step to the enhancement algorithm (unsharp masking). This combination approach resulted in a panel evaluation that judged the equalized images to be of higher quality than non-enhanced films and led to more accurate interpretation.

In an interesting study by Braunstein and associates,[108] 28 radiographs of destructive lytic skeletal lesions were digitized, and the resulting images were each subdivided into 25 equal regions. In each region an equalization transformation was computed and stored as a look up table, or LUT. (An LUT is

an efficient technique of applying a transformation, because the images are not changed, but simply translated on their way to the monitor or printer. No data is lost, and to change a characteristic for image study, only a new LUT need be installed, rather than a completely new image).[54] A panel of skeletal radiologists compared the digitized and equalized images. Statistical analysis (receiver operator characteristic, or ROC) demonstrated the superiority of equalized images for judging cortical intactness and periosteal reaction. No difference was determined regarding lesion or margin visibility, soft tissue mass, or trabecular definition. Additionally, in 80-100 percent of the cases, the equalized images were preferred on a qualitative basis. In their analysis the authors noted some inherent disadvantages of adaptive histogram equalization. Increase in contrast is inevitably accompanied by increased noise. Also, the same gray level in different regions may not mean the same thing, since the attenuation may be different in each area.

Computed tomography also would appear to be fertile ground for histogram modification. Lehr and Capek[109] explained that although CT equipment can produce over 2,000 levels of gray, current monitor-film systems do not yet have this capability. However, they quoted additional work by Pizer and Chan[110] reporting that human observers can reliably discriminate only about 88 different intensity levels. This poses a dilemma for radiologists, namely, whether to eliminate most of the CT grayscale to preserve the viewer's ability to discriminate low-contrast features, or to hinder this latter ability by making a larger portion of the CT scale visible. The authors theorized that histogram equalization might provide an optimal solution. The results of their

research inspired reflection on not only the technique, but also the viewers. The equalized images did improve the visibility of anatomic structures over a wide portion of the CT scale. However, the observers stated their preference for the unequalized images, citing, sometimes vehemently, the increased "noise" and "graininess" of the equalized images. Further research found that in spite of this quality, no degradation was detected in observer performance with these allegedly "unreadable" equalized images compared to standard CT images.

The problem of increased noise in equalized images led Rehm and associates[111] to develop what they described as a sophisticated enhancement algorithm called artifact-suppressed adaptive histogram equalization. The technique was adaptive in that the local characteristics within the image determined the transformation function used in that region. They used the innately difficult model of lung nodule detection in their research. Their results indicated initial success in providing contrast-enhanced, natural appearing chest images without loss of diagnostic information.

Future research will inevitably bring improvements in histogram modification techniques.

## EXAMINER PERCEPTION AND INTERPRETATION

Abercrombie[112] stated that "what is perceived depends not only on what is being looked at but on the state of the perceiver." Each person develops a "schema or schemata," a mental file of past information, reactions or experiences that affect present perception and interpretation. These internal schemata are very much a factor in radiographic interpretation. Perception may

not seem like an activity, *per se*, but Abercrombie related that for congenitally blind patients who were later cured, learning to see was complex and laborious; there is much time and effort required to build schemata. He continued by noting that radiologists learn to relate visual patterns to pertinent schemata that they have constructed through exposure to large numbers of radiographs. These specialists also know how to obtain further relevant information about what they see, relevant being defined as "that which tends to lead to the correct judgment."

Given the large portion of visual interpretation controlled by factors unique to the individual observer, it is no wonder that studies covering several decades have catalogued major observer discrepancies in radiological evaluation. There appears to be a dichotomy between the "general tendency to accept radiography as an exact science,"[113] and an interpretation process that is by its very nature highly subjective.[114]

Just how serious a problem there can be in observer agreement became quite clear in the late 1940s and early 1950s. Fletcher[115] designed an experiment in which ten physicians classified 102 chest radiographs into five categories of pneumoconiosis progression. Each physician viewed the films twice. Fletcher found their opinions differed markedly among themselves, and to a lesser degree from the first to the second viewing. There was serious disagreement concerning the limits of "normal" in these films. He found the amount of inconsistency "intolerable in view of the important consequences of the radiological diagnosis of pneumoconiosis."

Not long after this Yerushalmy and associates[116] found that in evaluating pairs of chest films obtained three months apart, experienced physicians disagreed in almost one-third of the cases. They disagreed with themselves approximately one out of five times from the first to the second viewing. Although films may still be the most dependable piece of evidence, the researchers echoed a refrain soon to be familiar, that radiographs must not be taken as the sole criterion of patient's progress, nor be the sole basis on which treatment decisions are made. They called for further research to determine what factors influenced film interpretation.

Koran[117,118] recognized a need to clarify the terminology of diagnostic interpretation and its statistical counterparts. Reliability simply meant whether the evaluators agreed. This agreement, in turn, might be of two types. Overall agreement refers to the proportion of patients about whom observers agree on the presence or absence of an abnormality. Specific agreement is limited to abnormality presence only, not its absence. Neither type factors in chance agreement, an element that can vary markedly. Koran also discussed the kappa statistic, a tool for statistical evaluation that takes chance into account.

Koran reviewed a variety of studies, including those of cardiovascular, gastrointestinal and respiratory signs, electrocardiography, electroencephalography, and radiography (osteoarthritis, pyelonephritis, ulcerative colitis, tuberculosis), and even physical examination, in which reliability varied widely. Overall, he found that physicians almost always disagreed in at least one in ten cases and often more than one in five.

"Disagreements of this magnitude, if characteristic of clinical practice in general, cannot safely be regarded as inconsequential."

Numerous studies have borne out Koran's concerns. Goldstein and Mobley[119] found dental radiograph interpretation not to be a stable and consistent process, and agreed that low reliability may be a pervasive problem. In their simple study, 40 senior dental students examined 40 bitewing radiographs twice, with a two hour gap between viewings. They were asked to determine the presence or absence of abnormality, and if abnormality were present, was it simply a processing error. Of the 80 slides examined only 73 percent were correctly classified. There was an extremely high (41 percent) false positive rate. Interrater agreement was 70 percent; intrarater agreement was 90 percent.

In a pair of studies by Goldman, Pearson and Darzenta,[120,121] six well-qualified examiners viewed 253 radiographs and judged whether the endodontic treatment rendered was or was not successful. In only 47 percent of the cases did all six examiners agree, while five of the six agreed only 67 percent of the time. Likewise, when determining the presence or absence of rarefaction, there was only 42 percent total agreement. In 71 percent of the cases five of six examiners agreed. Two years later three of the six original examiners repeated the experiment and demonstrated an agreement level of 75-83 percent. The authors believed that radiographs are a questionable means of determining success and failure since they are not *read* so much as *interpreted.*

Duinkerke and associates[122] approached the subject by different means. Ten dentists reviewed three sets of films with radiolucencies ranging from well-defined to diffuse. During each of two viewings the participants were asked to trace the contour of the roots and the radiolucencies. The areas within these tracings were calculated; the relative error for well-defined lesions averaged 21 percent and for diffuse lesions 37 percent.

Nielsen[123] reviewed intrarater and interrater agreement in reading periapical films taken immediately after endodontic therapy completion. In evaluating apical seal and the presence and extent of periapical changes, the examiners agreed with each other 65-75 percent and with themselves 75-90 percent of the time. Nielsen found no significant difference when comparing maxillary and mandibular teeth or among one, two or three rooted teeth.

Antrim[124] arranged for six examiners to review 260 single films for the presence of periapical pathosis. For each of three weekly viewings the examiners used a different method of examination, either holding the films up to a light box, projecting them onto a screen, or viewing them through a magnifier. The evaluators recorded complete agreement among themselves 44.2-52.3 percent of the time, with the viewbox being the best method of examination. There was a mean intrarater agreement of 68.8 percent. Antrim's research methods ruled out film density, the angle of the primary x-ray beam, and processing differences as explanations for the high level of disagreement.

Zakariasen, Scott and Jensen[125] had four examiners review a series of recall and postoperative radiographs. All four agreed only 38 percent of the time as to the status of the periapical area. Intrarater agreement ranged from

64.5-81.0 percent. The authors stated the obvious when they reported that unreliability is a major problem.

Gelfand, Sunderman and Goldman[126] asked 79 dentists to evaluate ten periapical radiographs that had been the subject of examiner disagreement in a previous study. In only five cases was there greater than 50 percent agreement. One of the five was a duplicate, thus there were actually only nine different radiographs present in the study. The nature of the test meant that the duplicate slides were projected onto a screen with only 2 1/2 minutes separating their display. Still, the intraevaluator disagreement rate for these two slides approached 22 percent. Little wonder that the authors acknowledged the indispensibility of radiographs while pointing out the necessity to consider the limitations of visual interpretation.

Wahab, Greenfield and Swallow[127] obtained almost absurdly low interrater agreement when they asked 12 dentists to evaluate the presence and extent of periapical pathology in 50 radiographs. First and second viewings were done three to five weeks apart, and agreement ranged from 0-2 percent. These scores did not significantly improve by subdividing the evaluator groups. Intrarater agreement averaged 47 percent with a range of 30-64 percent. The proportion of films that received the same score at both viewings ranged from 45-71 percent. The authors stressed the lack of association between experience level and the probability of correct interpretation.

Many researchers have recognized the problems of radiograph interpretation demonstrated by the above examples and proposed possible ways to minimize them. Brynolf[128,129] conducted a set of studies in which

examiner agreement and radiographic-histologic agreement were analyzed. The variable in both studies was the number of periapical films used in diagnosing each tooth in the study. Intrarater agreement improved from 70 percent to 87 percent by using three films instead of one. Likewise, the accuracy of diagnosis based on histologic examination improved from 74 percent to 90 percent with three films rather than one.

Brynolf[130] joined Welander and his colleagues[131] in stressing the importance of eliminating extraneous light during radiographic examination. Techniques included light-masking frame mounts, viewbox blackout, dimming of room lights, and possible use of optical viewers that permit more refined film density discrimination.

Kundel and Wright[132] analyzed the physiology of radiograph examination by charting the eye movements of radiologists while they viewed assorted chest films. They found that different search patterns were used for different tasks. The purpose of eye movement was to bring the areas of greatest interest into the region of greatest spatial resolution within the eye, the fovea centralis. Although there is obviously a vast difference in the degree of eye motion between chest and periapical films, the authors' conclusions are valid for both. Eye movement is a sampling process. The observer develops a strategy for the search appropriate to the stimulus and the task at hand. Search strategies may be reinforced, leading to the enhancement of the accuracy and reliability of the search.

On the other hand, tutorial reinforcement at times may be of limited benefit. Herman and Hessel[133] evaluated the effect of training level on the

accuracy of chest film interpretation. No statistically significant difference was found in the diagnostic accuracy of first, second and third year radiology residents and practicing radiologists. In fact, of the eight study participants, the one committing the fewest errors was a first year student. The researchers wrote that innate "individual abilities, perceptual and otherwise, may have a stronger influence on accuracy than the length of formal training."

Along with individual abilities, search habits may play a role in diagnostic accuracy. Tuddenham[134] hypothesized that many omissions were due to the premature termination of the search, i.e. after detecting something important the evaluator simply quits looking at the rest of the film. He also believed that perception of ambiguous patterns within films might be strongly influenced by external factors such as a relevant index of suspicion or a knowledge of the clinical history.

Gröndahl[135] concurred with Tuddenham, believing that information given prior to radiographic examination could change observer performance to such an extent that epidemiological investigations might be tainted. He reported a simple experiment in which evaluators examined a set of films twice, but with adequate time between viewings to prevent a significant effect on results due to simple memory. Prior to one viewing it was announced that 75 percent of the films demonstrated carious lesions; for the other viewing the carious incidence was reported as 25 percent. It was found that 20 percent of all evaluated surfaces received a different diagnosis on the second reading. Even though additional training was provided and diagnostic criteria were reviewed prior to the examination, wide variation among observers still occurred.

The clinical history may be a vital feature in improving diagnostic accuracy. Schreiber[136] reported a statistically significant improvement in diagnostic performance when evaluators had knowledge of clinical findings, mainly due to a decrease in false negatives. Swensson and colleagues[137] attributed this not to an enhancement of visual perception of abnormalities, but rather to the ability to "judge more accurately which ambiguous radiographic features should and should not be reported."

Koran[138] offered many suggestions to improve examiner reliability, most of which were directed to the education process. Among others, these proposals included more careful definition of terminology, more studies on decision-making techniques, and fewer qualitative criteria used during radiographic evaluation.

Brynolf[139] developed a detailed sign-analyzing method of radiographic interpretation. Each film was reviewed using nine criteria, most of which contained several categories. Criteria suggested included bone structure, shape of the PDL, and shape of the pulp chamber. Bone structure, incidently, was stated to be the single most differentiating detail in radiographic evaluation. In a study of 292 maxilary incisors, these exacting criteria led to improvement of diagnostic accuracy, i.e. matching the true histological diagnosis, to a rate exceeding 90 percent. Evaluators were commonly able to distinguish disease presence from absence and mild disease from severe.

Valachovic and associates[140] acknowledged that reliable interpretation is easily affected by observer biases, whether they be educational, experiential, technical or clinical. To quantify observer bias or diagreement is a daunting

task, exemplified by the previously mentioned Kappa statistic. Valachovic explained that the problem with Kappa is that dental diagnoses are often ordinal and not nominal, thus some diagreements are more serious than others. In deference to this fact, they supported using the weighted Kappa ($K_w$), which is the proportion of weighted agreement corrected for chance. Unfortunately, assigned weights to various data is in itself an arbitrary exercise. This weakness is not disqualifying, however. In a test of their ideas the authors attempted to calibrate the observers by leading standardization sessions and practice periods. Their goal was to achieve higher levels of inter- and intrarater agreement for caries and periodontal disease evaluation. They concluded that Kappa is an appropriate estimate of examiner reliability, that $K_w$ did not offer statistically significant advantages based on the weights assigned, and that standardization sessions led to initial and sustained high levels of inter- and intrarater agreement.

Eckerbom, Andersson and Magnusson[141] agreed on the importance of extensive calibration to increase viewer agreement. They found a decrease in the error rate if the examiners were trained together.

# METHODS AND MATERIALS

## SPECIMENS

Human jaw cadaver specimens were obtained from the Indiana University School of Medicine Department of Anatomy. These were grossly debrided with a #15 Bard Parker blade (Bard Parker, Becton Dickinson and Co., Lincoln Park, N.J. 07035) and other hand instruments. Inaccessible soft tissue tags were removed by immersing the specimens in a 2.5 percent NaOCl solution for 24 hours, followed by a tapwater rinse. Vinyl polysiloxane putty (Exaflex, GC America Inc., Chicago, Ill. 60658) was placed along the occlusal and lingual surfaces of all teeth in each jaw specimen and allowed to set. Each jaw section was then placed in a bench-top vise, and selected teeth were extracted with appropriate exodontic forceps. Minimal rocking forces were applied during each extraction, but if required, the force used was only in a slight bucco-lingual axis. If there were no evidence of root or bone fracture, the teeth were properly repositioned in the sockets by using the previously fabricated putty stents. The jaws were then sectioned in a bucco-lingual plane, producing 21 specimens for further screening. These segments were radiographically evaluted using the following criteria:

a. no evidence of periapical pathosis.

b. no manmade objects within bone or root.

c. reproducible repositioning of the root within the socket.

Fifteen specimens were suitable for study (4 maxillary, 11 mandibular).

## LESION CREATION

Periapical lesions were created in each specimen by removing the teeth, placing a cotton pellet at the apex of the socket, and saturating the pellet with 0.10 cc of 70 percent perchloric acid. The sockets were then capped with small vinyl polysiloxane plugs. Prior to each RVG exposure, the cotton pellets were removed, the sockets were gently blotted with cotton-tip applicators to remove any demineralized bone, and the teeth were repositioned in the sockets. After each exposure (except the last), the teeth were removed and fresh acid was applied. This sequence was repeated at time intervals of 2, 4, 8, 12, 16 and 24 hours until the allotted time had expired. The specimens were rinsed thoroughly, then immersed in tap water for 24 hours.

## RADIOGRAPHIC TECHNIQUE

To ensure consistent x-ray cone angulation, a plexiglass positioning device was used, consisting of an 11x4 inch base, a specimen mounting site, a 1-inch tissue equivalency plexiglass block and 2 clamps to hold the x-ray cone in proper and reproducible alignment. For each specimen, vinyl polysiloxane putty was adapted to the positioning device, and while the putty remained soft, both the CCD sensor and the specimen were pressed into it. Once hardened, the putty allowed quick realignment of specimen and sensor prior to each image capture. The source-to-sensor distance approximated that found in routine paralleling technique oral radiography.

Exposure settings on the RVG system were as follows:

a. RVG mode.

b. 70kvp, 8 mA.

c. "Film type" 2 (corresponding to the setting recommended for Kodak Ektaspeed film if conventional radiography is used with the RVG unit).

d. .04 second exposure time for all posterior teeth, except one premolar (Specimen N), and .02 second exposure time for all others.

Images were captured prior to acid application, then at 2, 4, 8, 12, 16 and 24 hours after acid application. A total of 105 radiographic exposures were made (15 specimens x 7 time periods) in the linear setting on the RVG system, then transferred by floppy disc to the Indiana University School of Dentistry (IUSD) computer network server for storage and future retrieval (Microsoft Windows File Manager 3.1; Microsoft Corporation, Bothell, Wash. 98041). Each image required appoximately 182,400 kilobytes of memory. Once the images were stored, each was individually retrieved and copied 4 times. Each copy was altered in a different way, three of the four by using software designed for photographic retouching, color painting and image editing. (Adobe Photoshop 2.5.1, Adope Systems Inc, Mountain View, Calif. 94039). The grayscale image was pseudocolor-enhanced in one copy by adapting the "Black Body" menu item. This enhancement "displays a transition of colors based on the different colors a blackbody radiator emits as it is heated: from black to red, orange, yellow, and white."[142]

The grayscale contrast was reversed in the second copy. "Global" histogram equalization was performed on the third copy. The fourth copy was altered by "regional" histogram equalization using techniques now in development at IUSD.

The 525 images were randomized and loaded into a slide show format (Astound for Windows, Gold Disk Inc, Mississawga, Ontario, Canada L5M2C2) for future viewing by the evaluators. In each image, a small "X" was superimposed over the root to ensure the correct socket was evaluated.

## EVALUATION PROCEDURES

Images were displayed on a 21-inch color monitor in a viewing room with standard fluorescent ceiling lights turned on. The images were 5.9 inches wide by 7.5 inches high (15 x 19 cm) and were centered on a black background. The slide number was displayed below each image.

Five evaluators from the Indiana University Department of Endodontics each viewed the slide sequence twice, with time between viewings ranging from 3 to 8 days. Due to the large number of images, each viewing was conducted in two sessions, the first covering 275 images and the second 250 images. All sessions were conducted in the morning. Three evaluators were experienced endodontists, and two were endodontic residents with at least five years of general dentistry practice.

The following instructions were given to each evaluator:

> Any "thickening" of the PDL, discontinuity of the lamina dura or osseous radiolucency which would normally be considered pathologic in routine endodontic practice should be considered pathologic for the purposes of this study.

The following scale was used in the evaluation:

5. Lesion definitely present.

4. Lesion probably present.

3. Lesion presence cannot be determined.

2. Lesion probably not present.

1. Lesion definitely not present.

A laptop computer was placed next to the video monitor, and each evaluator entered his scores directly into a spreadsheet program (Sigma Plot, Jandel Scientific, San Rafael, Calif. 94912). No time limit was placed on the evaluators, but they were encouraged to complete their viewings with dispatch.

## STATISTICAL ANALYSIS

At each time point, an analysis of variance model was fitted to the first set of rankings given by the evaluators. These analyses were used to determine if the average scores differed significantly between the 5 digital image types at each time point. Multiple comparisons were made using least significant differences or Tukey's method at an overall confidence level of 95 percent. Interrater and intrarater agreement were assessed using the Kappa statistic and the intraclass correlation coefficient. Statistical analysis determined the correlation of image enhancement type to lesion detection accuracy, and the interrater variability and intrarater reproducibility.

# RESULTS

The third generation RadioVisioGraphy system, RVG-S, was used to capture radiographic images of simulated periapical lesions. This study compared the relative diagnostic merits of the original linear image and four enhanced versions. Images were scored for evidence of lesion presence at seven time points, from 0 to 24 hours after application of 70 percent perchloric acid, a demineralizing agent. Rater scores at each time interval were compared to determine if any enhancement method allowed earlier visualization of the lesions. Additionally, interrater variability and intrarater reproducibility were calculated.

The first set of scores for each evaluator was analyzed to determine if significant differences existed in demonstration of early periapical lesions among the five image types. At each time point, an analysis of variance model was fit to the scores. Multiple comparisons were made using Tukey's method at an overall 95 percent confidence level. At hour 0, or immediately prior to acid application, the linear and reverse contrast image scores were significantly lower than global histogram equalization ($p=.0098$). At hours 2 and 4, no image type had significantly different scores from the others. At hour 8, both global and regional histogram equalization had significantly higher scores than reverse contrast ($p=.0027$). At hours 12, 16, and 24, pseudocolor-enhanced and linear image scores, as well as global and regional histogram equalized image scores, were all significantly higher than reverse contrast image scores ($p=.0006$, $p=.0001$, and $p=.0001$, respectively).

Further comparisons were made to ascertain whether any significant differences existed among the image types if reverse contrast images were excluded from the analyses. At hour 0, global histogram equalization scores were significantly higher than color enhanced as well as linear images (p=.0068). At hour 8, both types of histogram equalization had significantly higher scores than linear images (p=.0112). No other differences were noted from the deletion of reverse contrast scores.

Intrarater reproducibility was evaluated by comparison of the two scores given to each image. The Intraclass Correlation Coefficient and Kappa Statistic were used for statistical analysis. The agreement level of the latter is routinely described as fair if in the range of 0.21-0.40, moderate if 0.41-0.60, and substantial if 0.61-0.80. Overall, the evaluators in this study demonstrated a moderate relationship between the scores given at the two viewings (Tables I-IV).

Interrater agreement was also determined using the same two statistical models. The first set of scores given to each image were used for this comparison. Using the same scale as noted above, all evaluators demonstrated only a fair level of agreement (Tables V-VIII).

There also did not appear to be any major differences in intrarater reproducibility between maxillary and mandibular samples. However, due to the small number of maxillary specimens (4 of 15), conclusions could not be reliably drawn.

# FIGURES AND TABLES



FIGURE 1. Specimen mounted on paralleling device.




FIGURE 2. Examiner viewing arrangements.

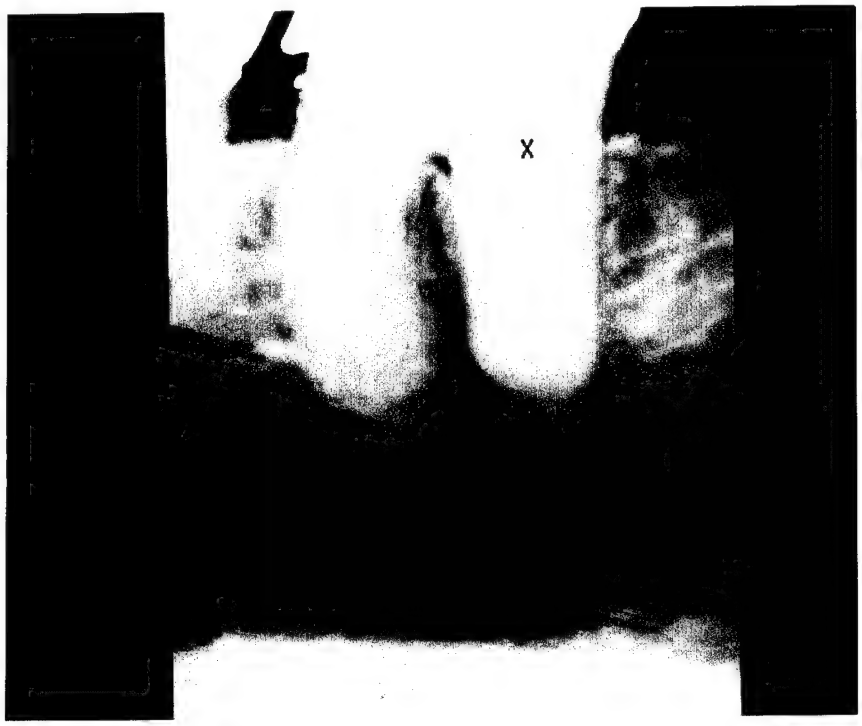


FIGURE 3. Specimen C at 24 hours - linear setting.

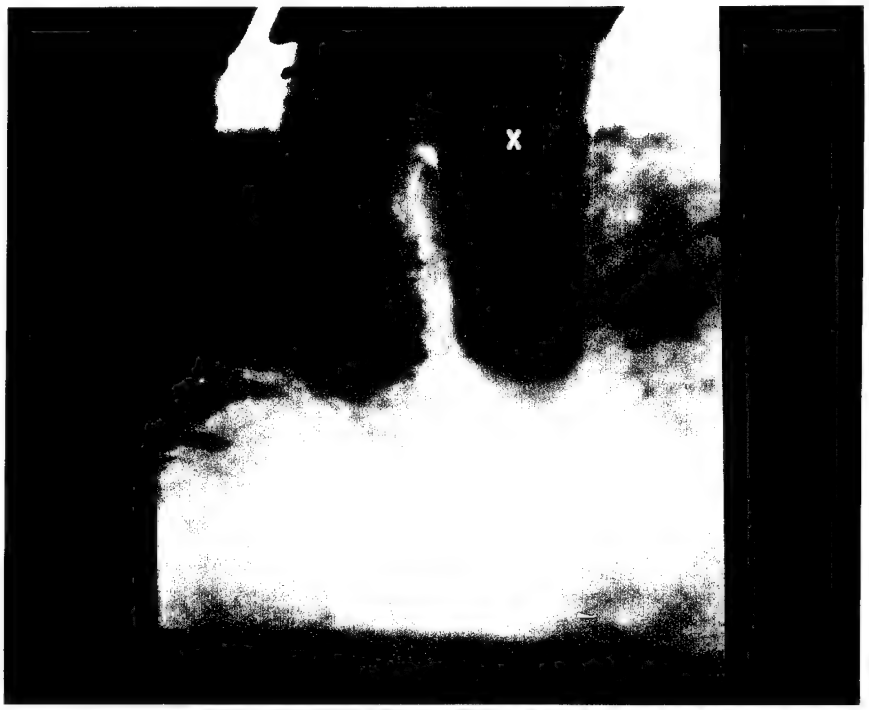


FIGURE 4. Specimen C at 24 hours - reverse contrast.

FIGURE 5. Specimen C at 24 hours - pseudocolor enhancement.

FIGURE 6. Specimen C at 24 hours - global histogram equalization.

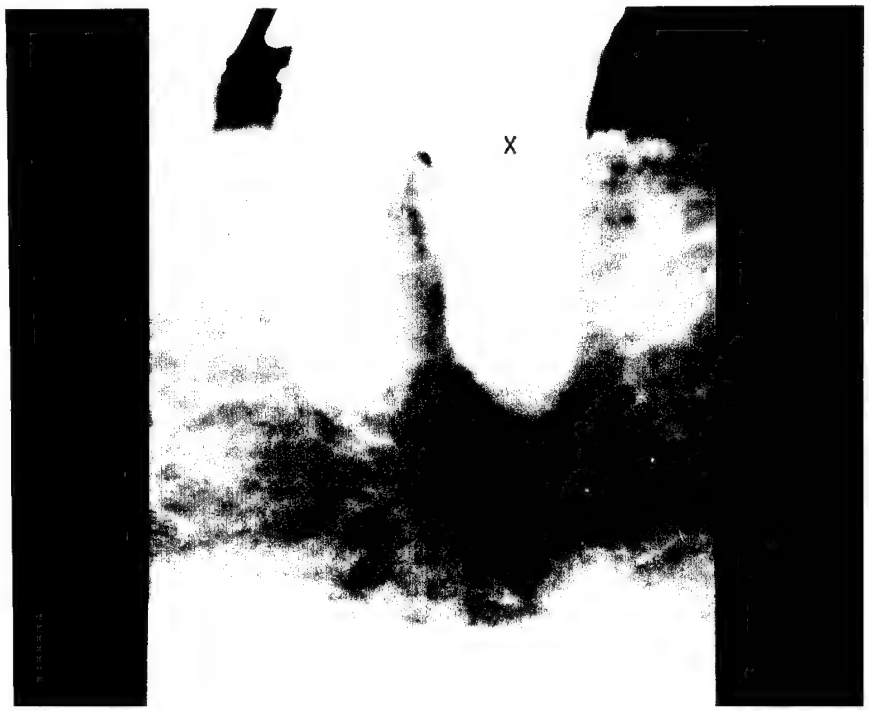


FIGURE 7. Specimen C at 24 hours - regional histogram equalization.

TABLE I

INTRARATER REPRODUCIBILITY
Intraclass correlation coefficient

| Examiner | Overall | w/o Reverse Contrast |
|---|---|---|
| A | .65 | .67 |
| B | .66 | .64 |
| C | .61 | .54 |
| D | .51 | .47 |
| E | .70 | .74 |

TABLE II

INTRARATER KAPPA STATISTIC
All times

| Examiner | Overall | w/o Reverse Contrast |
|---|---|---|
| A | .52 | .54 |
| B | .56 | .55 |
| C | .52 | .45 |
| D | .47 | .43 |
| E | .55 | .58 |

TABLE III

INTRARATER KAPPA STATISTIC
Hour 0

| Examiner | Overall | w/o Reverse Contrast |
|---|---|---|
| A | .48 | .48 |
| B | .45 | .42 |
| C | .34 | .30 |
| D | .44 | .21 |
| E | .60 | .30 |

TABLE IV

INTRARATER KAPPA STATISTIC
Hour 24

| Examiner | Overall | w/o Reverse Contrast |
|---|---|---|
| A | .56 | .49 |
| B | .69 | .59 |
| C | .38 | 0 |
| D | .56 | .20 |
| E | .45 | .48 |

TABLE V

INTERRATER VARIABILITY
Intraclass correlation coefficient

| Time | Overall | w/o Reverse Contrast |
|---|---|---|
| Hour 0 | .27 | .25 |
| Hour 24 | .39 | .14 |
| All Times | .34 | .33 |

TABLE VI

INTERRATER KAPPA STATISTIC
All times

| | Overall | | | | w/o Reverse Contrast | | | |
|---|---|---|---|---|---|---|---|---|
| Rater | E | D | C | B | E | D | C | B |
| A | .32 | .30 | .25 | .28 | .31 | .31 | .26 | .29 |
| B | .26 | .35 | .26 | | .27 | .32 | .24 | |
| C | .14 | .28 | | | .13 | .30 | | |
| D | .26 | | | | .26 | | | |

TABLE VII

INTERRATER KAPPA STATISTIC
Hour 0

| | Overall | | | | w/o Reverse Contrast | | | |
|---|---|---|---|---|---|---|---|---|
| Rater | E | D | C | B | E | D | C | B |
| A | .19 | .15 | .22 | .04 | .18 | .13 | .23 | .02 |
| B | .14 | .31 | .25 | | .15 | .32 | .23 | |
| C | .19 | .35 | | | .08 | .39 | | |
| D | .33 | | | | .32 | | | |

TABLE VIII

INTERRATER KAPPA STATISTIC
Hour 24

| | Overall | | | | w/o Reverse Contrast | | | |
|---|---|---|---|---|---|---|---|---|
| Rater | E | D | C | B | E | D | C | B |
| A | .20 | .42 | .18 | .40 | .20 | .22 | .26 | .30 |
| B | .25 | .59 | .20 | | .01 | .38 | .22 | |
| C | .02 | .13 | | | -.05 | .02 | | |
| D | .28 | | | | .08 | | | |

# DISCUSSION

The purpose of this study was to explore the diagnostic potential of digital image enhancement as it relates to detection of periapical lesions in bone. Previous studies have documented the relative merits of digital and conventional radiographic images,[4,71-74,79,81] but little information exists in the endodontic literature as to how the wide spectrum of digital manipulation might be best applied to clinical diagnostic tasks.

## LESION PREPARATION

Simulated periapical lesions within the tooth socket were created by using a 70 percent solution of perchloric acid at selected time intervals. This technique allowed demineralization to proceed in the same manner as lesions of endodontic origin; namely, from the tooth socket into the surrounding cancellous bone and then to or through the cortical-medullary junction and cortex. It also allowed a more realistic radiographic appearance by preventing the creation of sharp edges at the lesion borders. Gross examination of some specimens after 24 hours of acid application revealed paths of demineralization that did not necessarily correspond with common, somewhat spherical lesion architecture. This was more notable in anterior jaw specimens where the tooth socket is at least partially continuous with the buccal cortex.[11] However, this departure from the norm might not necessarily have been a significant contributor to the statistical results, since the main thrust of the project was to study early lesion visualization rather than late.

Still, improvements in the technical aspects of acid application for selective demineralization are certainly possible in future studies. Although the placement of a cotton pellet at the apex of the socket did retard drainage of any pooled acid through socket porosities, gravity ultimately determined the direction of demineralization progression. It is commonly accepted that pathologic lesions spread toward and through the path of least resistance within the jaw, although the processes involved are less well understood. Attention might be given in future studies towards methods of more precise and controlled acid flow within a jaw specimen. This would allow even more realistic lesion simulation and a corresponding increase in the reliability and relevance of experimental data.

## ANALYSIS OF RESULTS

Statistical analysis of evaluator performance in this study supports previous research showing that radiographic interpretation is not a stable and consistent process. Low levels of examiner agreement are a pervasive problem.[117-127] In this study, interrater agreement was judged as being only slight to fair, and intrarater agreement was determined to be moderate. These results are inferior to those reported by Goldman,[120,121] Duinkerke,[122] Nielsen[123] and Antrim.[124] They are somewhat comparable to studies by Zakariasen,[125] Gelfand[126] and Wahab.[127] Still, the relatively low agreement is troubling, for it casts some doubt as to the overall reliability of image interpretation.

Certain decisions were made regarding study design that were directed toward simulating normal clinical conditions. For instance, since RadioVisioGraphy and other digital imaging systems are designed to be used chairside, ambient room light was not dimmed, although it is known that reduced room light will often improve reader accuracy.[130,131] However, efforts were made to optimize viewing conditions on the screen by projecting the images onto a black background, thus minimizing visual distraction.

Instructions to each evaluator were kept to a minimum. Since four of the five image manipulations are virtually alien to most clinicians, there was some curiosity as to how the examiners' perception and interpretation skills would respond to these variations. No additional information was given, for instance, regarding the color gradient used in pseudocolor enhancement. One interesting development was the unsolicited comment by at least three of the evaluators that more interpretative instructions would have been desirable. This is almost an intuitive agreement with Gröndahl,[135] Schreiber[136] Swensson[137] and others, who showed that ancillary information provided to evaluators had a strong influence on observer performance.[138,141] It is possible that a new panel of five evaluators trained prior to image viewing as suggested by Eckerbom[141] might demonstrate much higher levels of agreement.

One disturbing result of statistical analysis was the relatively poor performance of all evaluators in rating images made at 0 and 24 hours after initial acid application. The fifteen specimens used were considered to be a random sampling of relatively normal jaws. Specimens with obvious periapical rarefactions were not used. Only one specimen demonstrated a bony

rarefaction near the root, but the lamina dura was clearly continuous around the adjacent root and not continuous with the rarefaction, an appearance not unlike that caused by the mental foramen in mandibular periapical films. In spite of this, interrater agreement was actually lower for hour 0 than overall interrater agreement (Tables V-VIII). Additionally, lesion presence was judged to be rather obvious at hour 24 in most images during specimen preparation, so much so that an initial plan to extend the acid application to 36 hours was judged unneccesary. Yet, agreement between raters was virtually the same at this end point as overall. The reproducibility and variability measures should be higher at the start and finish points. Evaluators should have been able to agree consistently that no lesions existed at hour 0 and that lesions definitely existed at hour 24, at least in the relatively familiar linear format. This trend toward diagreement at the end points suggests that at no time in between might there have been truly consistent ratings. This increases the difficulty of finding true differences in the diagnostic usefulness of the various image settings.[143]

Under the conditions of this study, the reverse contrast setting was not helpful in visualizing periapical lesions. From hour 12 of the study through hour 24, all other settings resulted in significantly higher certainty of lesion presence. Yet at hour 0, when no lesions were present, reverse contrast led to greater certainty of lesion absence than at least one other image type. Thus it might be suggested that reverse contrast images are more likely to be beneficial in confirming absence of a lesion rather than its presence. An equally valid conclusion might be that reversing the grayscale on a periapical image is of no particular benefit and caused the evaluators to be hesitant about affirming

lesion presence. The years of training and experience with which each evaluator approaches radiographic interpretation are not easily ignored, i.e. dark spots in an image mean loss of mineralization to the average clinician. Although a white spot might stand out clearly to an observer, as would normal tooth contour, an area of mid-density might be confusing and a dark spot hard to ignore. It would seem that considerable experience might be required to master the nuances of reverse contrast image interpretation. As stated by Kundel and Wright,[133] eye movement is a sampling process in which the area of greatest interest is brought into the zone of greatest spatial resolution. While most clinicians undoubtedly have at least subconscious search patterns in their review of periapical films, dark areas at the root apices must almost certainly draw attention first. Subtle shade differences indicating presence or absence of lamina dura continuity are also keenly examined. Whether the eye would be as quick to move to these key areas if a radiolucent area were indicated by lower densities would seem to be a question open to debate. However, contrast reversal combined with some other manipulative technique, such as edge enhancement, may someday prove valuable.

Histogram equalization would seem to be a tool worthy of further exploration. At first glance both variations used in this study seemed to have the same ability to demonstrate radiolucencies, as indicated by the results from hours 8 through 24. However, global equalization appears to have led to a higher incidence of false positives at hour 0. Regional (or adaptive) histogram equalization, within the parameters of this study, emerges as a viable tool for the clinician. Since it is essentially a mathematical process, many adaptive

formulas might be compared in future research, each giving weight to different areas or qualities within a digital image.

Comparison of pseudocolor-enhanced and linear image scores did not demonstrate statistically significant differences. However, pseudocolor enhancement appears to be an area ripe for further research. Its potential seems unmatched, due to the keen color acuity of the human visual system and the three-dimensional nature of color, compared to the unidimensional nature of grayscale images. In this study a spectrum of colors corresponding to the so-called heat scale was used. When heated, some physical objects pass through a range of colors as their temperature increases, i.e. red to yellow to yellow-white. The grayscale images were enhanced such that denser areas were shaded red. As density of the image decreased, the enhancement shifted to yellow and yellow-white shades. As stated above, even without prior explanation of the shading scheme, the evaluators did not appear to have any special difficulty in interpreting the images. Whether they had intuitive understanding of this color spectrum cannot be determined. Since these shades did not cover the full visible spectrum of light, it may be surmised that the evaluators' color vision was neither fully challenged nor fully exploited. Future research possibilities in pseudocolor enhancement appear almost limitless, but the choice of spectra might determine the learning curve involved in image interpretation.

# SUMMARY AND CONCLUSIONS

This study was designed to investigate the rapidly advancing realm of direct digital imaging as it relates to the detection of periapical radiolucencies of endodontic origin. The tools employed in this project were pseudocolor enhancement, contrast reversal, global histogram equalization and regional histogram equalization. These image modifications were compared with standard linear images of simulated periapical radiolucencies to determine if earlier certainty of lesion presence was attainable.

Fifteen cadaver jaw specimens were used. A 70 percent solution of perchloric acid was applied to one tooth socket of each specimen after initial digital image capture, followed by sequential imaging at 2, 4, 8, 12, 16 and 24 hours after acid application. Each of the 105 linear images was then modified using the four manipulations cited above. This meant that each specimen had five image formats for display at each time point. The 525 images were displayed in random order on a standard color monitor in a slideshow format. Images were superimposed on a black background and viewed in ambient room light.

Five examiners individually viewed each image twice, with an interval of 3-8 days between viewings. Written instructions defined positive lesion presence; however, no additional explanation was given as to the nature of the various enhancements. Examiners assigned a numerical score to each image based on their certainty of lesion presence or absence. No time limit was

placed on the examination; each image could be viewed as many times as desired during the course of the viewing session.

Interrater variability and intrarater reproducibility were determined by using the Kappa Statistic and Intraclass Correlation Coefficient statistical models. Analysis of variance and Tukey's method were used to ascertain whether significant differences existed in lesion perceptibility among the various image types and times.

Interrater agreement was determined to be only fair, with a Kappa statistic average of 0.27 (range 0.14-0.32). Intrarater agreement, using the same methods, was judged to be moderate, with a Kappa statistic average of 0.53 (range 0.47-0.56). There was no substantial improvement in the levels of agreement at either endpoint (hours 0 and 24). At hour 0, reverse contrast and linear image scores were significantly lower than those for global histogram equalization, indicating a higher rate of false positives for the latter when no lesion existed. At hour 8, both types of histogram equalization had significantly higher scores than reverse contrast images. At hours 12, 16 and 24, reverse contrast image scores were significantly lower than all other types.

Within the framework of this study, it may be concluded that histogram equalization and pseudocolor enhancement are viable methods of image transformation in the detection of periapical radiolucencies. However, calibration of diagnostic criteria and familiarization with enhancement techniques and appearance may lead to higher levels of examiner agreement and more accurate interpretation of periapical images. As direct digital imaging

becomes more widespread in clinical endodontic practice, further investigation is warranted as to the diagnostic utility of these and other image enhancements.

# REFERENCES

1. Bender IB, Seltzer S. Roentgenographic and direct observation of experimental lesions in bone. I. J Am Dent Assoc 1961;62:152-60.

2. Bender IB, Seltzer S. Roentgenographic and direct observation of experimental lesions in bone. II. J Am Dent Assoc 1961:62:708-16.

3. Lee SJ, Messer HH. Radiographic appearance of artificially prepared periapical lesions confined to cancellous bone. Int Endod J 1986;19:64-72.

4. Tirrell B. Interpretation of chemically created lesions using direct digital imaging [Thesis]. Indianapolis: Indiana University School of Dentistry, 1994;3-86.

5. Swartz DB, Skidmore AE, Griffin JA Jr. Twenty years of endodontic success and failure. J Endod 1983;9:198-202.

6. Matsumoto T, Nagai T, Kazuhiko I, et al. Factors affecting successful prognosis of root canal treatment. J Endod 1987;13:239-42.

7. Razzano MR, Bonner PJ. Radiovisiography: video imaging alters traditional approach to radiography. Compend Contin Educ Dent 1990;11:398-400.

8. Miles DA. Imaging using solid-state detectors. Dent Clin N Amer 1993;37:531-40.

9. Alfano B, Brunetti A, Ciarmiello A, Salvatore M. Simultaneous display of multiple MR parameters with "quantitative magnetic color imaging". J Comp Assist Tomogr 1992;16:634-40.

10. Manson-Hing LR. Vision and oral radiography. Oral Surg Oral Med Oral Pathol 1962;15:173-83.

11. Goldman HM, Millsap JS, Brenman HS. Origin of registration of the architectural pattern, the lamina dura, and the alveolar crest in the dental radiograph. Oral Surg Oral Med Oral Pathol 1957;10:749-58.

12. Manson JD. The lamina dura. Oral Surg Oral Med Oral Pathol 1963;16:432-8.

13. Kilpinin E, Hakala PE. Reproduction of the lamina dura in dental radiographs. Dentomax Radiol 1978;7:51-4.

14. Shafer WG, Hine MK, Levy BM. A textbook of oral pathology. 4th ed. Philadelphia: WB Saunders Co, 1983:658-61.

15. Paris L. A change in dental lamina dura terms for the clinician. J Maine Med Assoc 1966;57:134.

16. Kaffee I, Tamse A, Schwartz Y, Buchner A, Littner MM. Changes in the lamina dura as a manifestation of systemic diseases: report of a case and review of the literature. J Endod 1982;8:467-70.

17. Elfenbaum A. Alveolar lamina dura radiographic interpretation. Den Radiol Photog 1958;31:21-9.

18. Kaffee I, Gratt BM. Variations in the radiographic interpretation of the periapical dental region. J Endod 1988;14:330-5.

19. Prichard JF. Advanced periodontics: surgical and prosthetic management. Philadelphia: WB Saunders Co, 1965. Cited in: Schwartz S, Foster J. Roentgenographic interpretation of experimentally produced bony lesions: Part I. Oral Surg Oral Med Oral Pathol 1971;32:607-12.

20. Borak J. Relationship between the clinical and roentgenographical findings in bone metastasis. Surg Gyneco Obstet 1942;75:599-604.

21. Shackman R, Harrison CV. Occult bone metastases. Br J Surg 1948:35:385-9.

22. Ardran GM. Bone destruction not demonstrable by radiography. Br J Radiol 1951;24:107-9.

23. Ramadan AE, Mitchell DF. A roentgenographic study of experimental bone destruction. Oral Surg Oral Med Oral Pathol 1962; 15:934-43.

24. Pauls V, Trott JR. A radiological study of experimentally produced lesions in bone. Dent Practit 1966;16:254-8.

25. Regan JE, Mitchell DF. Evaluation of periapical radiolucencies found in cadavers. J Amer Dent Assoc 1963;66:529-33.

26. Schwartz S, Foster J. Roentgenographic interpretation of experimentally produced bony lesions. Part I. Oral Surg Oral Med Oral Pathol 1971;32:607-12.

27. van der Stelt PF. Experimentally produced bone lesions. Oral Surg Oral Med Oral Pathol 1985;59:306-12.

28. Shoha RR, Dowson J, Richards AG. Radiographic interpretation of experimentally produced bony lesions. Oral Surg Oral Med Oral Pathol 1974;38:294-03.

29. LeQuire AKK, Cunningham CJ, Pellen GB Jr. Radiographic interpretation of experimentally produced osseous lesions of the human mandible. J Endod 1977;3:274-6.

30. Pitt-Ford TR. The radiographic detection of periapical lesions in dogs. Oral Surg Oral Med Oral Pathol 1984;57:662-7.

31. Glasser O, Quimby EH, Taylor LS, Weatherwax JL, Morgan RH. Physical foundations of radiology. 3rd ed. New York: Paul Hoeber, Inc., 1961:1-22.

32. Goaz PW, White SC. Oral radiology: principles and interpretation. 3rd ed. St. Louis: CV Mosby, 1994:1-23.

33. Selman J. The fundamentals of x-ray and radium physics. 7th ed. Springfield, Illinois: Charles C. Thomas, 1985:145-385.

34. Whaites E. Essentials of dental radiography and radiology. Edinburgh: Longman Group, 1992:13-20.

35. Wuehrmann AH, Manson-Hing LR. Dental radiology. 5th ed. St. Louis: CV Mosby, 1981:1-53.

36. Kasle MJ, Langlais RP. Basic principles of oral radiography. Volume 4. Philadelphia: WB Saunders, 1981:9-15.

37. Webber RL, Ryge G. The significance of exposure parameters in dental radiography. Oral Surg Oral Med Oral Pathol 1969;27:740-53.

38. Manson-Hing LR. Kilovolt peak and the visibility of lamina dura breaks. Oral Surg Oral Med Oral Pathol 1971;31:268-73.

39. Thunthy KA, Manson-Hing LR. Effect of mAs and kVp on resolution and on image contrast. Oral Surg Oral Med Oral Pathol 1978;46:454-61.

40. Glickman GN. Preparation for treatment. In: Cohen S, Burns RC, eds. Pathways of the pulp. 6th ed. St. Louis: CV Mosby, 1994:77-109.

41. Boyle WS, Smith GE. Charge coupled semiconductor devices. Bell System Technical J, April 1970: 587-93.

42. Photometrics Ltd. Charge-coupled devices for quantitative electronic imaging. Tucson: 1991.

43. Rose A, Weimer PK. Physical limits to the performance of imaging systems. Physics Today 1989 (Sept):24-32.

44. Brooks S, Miles DA. Advances in diagnostic imaging in dentistry. Dent Clin N Am 1993;37:91-111.

45. Hiraoka Y, Sedat JW, Agard DA. The use of a charge-coupled device for quantitative optical microscopy of biological structures. Science 1987;238:36-41.

46. Takahashi M, Ueno S, Tsachigame T, et al. Development of a 2,048 x 2,048 pixel image intensifier-TV digital radiography system. Invest Radiol 1992;27:898-907.

47. Gröndahl HG. Digital radiography in dental diagnosis: a critical review. Dent Maxillofac Radiol 1992;21:198-202.

48. Parks, ET, Miles DA, Van Dis ML, Williamson GF, Razmus TF, Bricker SL. Effects of filtration, collimation, and target-receptor distance on artificial approximal enamel lesion detection with the use of RadioVisioGraphy. Oral Surg Oral Med Oral Pathol 1994;77:419-26.

49. Dunn SM, Kantor ML. Digital radiography: facts and fictions. J Amer Dent Assoc 1993;124:39-47.

50. Ishida M, Doi K, Loo L, Metz CE, Lehr JL. Digital image processing: effect on detectability of simulated low contrast radiographic patterns. Radiology 1984;150:569-75

51. Farman AG, Scarfe WC. Pixel perception and voxel vision: constructs for a new paradigm in maxillofacial imaging. Dentomaxillofac Radiol 1994;23:5-9.

52. Smathers RL, Brody WR. Digital radiography: current and future trends. Br J Radiol 1985;58:285-307.

53. Skov Sj, Sewerin LP. Prototype system for archiving and transmitting digitized radiographs. Dentomaxillofacial Radiol 1993;22:99-101.

54. Niblack W. An introduction to digital image processing. London: Prentiss-Hall International, 1986:13-31.

55. Frost M, Staab EV. Displays: contrast and spatial requirements. Invest Radiol 1989;24:95-8.

56. Moystad A, Svanaes DB, Larheim TA, Gröndahl H-G. Dental digital versus conventional radiography: CRT display format and observer performance [Abstract]. Dentomaxillofac Radiol 1994;23:61.

57. Wenzel A. Effect of varying gray-scale resolution for detectability of bone lesions in intraoral radiographs digitized for teletransmission. Scand J Dent Res 1987;95:483-92.

58. MacMahon H, Vyborny CJ, Metz CE, Doi K, Sabeti V, Solomon SL. Digital radiography of subtle pulmonary abnormalities: an ROC study of the effect of pixel size on observer performance. Radiology 1986;158:21-26.

59. Giber ML, Doi K. Investigation of basic imaging properties in digital radiography. 3. Effect of pixel size on SNR and threshold contrast. Med Phys 1985;12:201-8.

60. Wenzel A, Fejerskov O, Kidd E, Joyston-Bectal S, Groeneveld A. Depth of occlusal caries assessed clinically, by conventional radiographs, and by digitized, processed radiographs. Caries Research 1990;24:327-33.

61. Wenzel A, Pitts N, Verdonschot EH, Kalsbeek H. Developments in radiographic caries diagnosis. J Dent 1993;21:131-40.

62. van der Stelt PF, van der Linden LWJ, Geraets WGM, Mons CL. Digitized pattern recognition in the diagnosis of periodontal bone defects. J Clin Perio 1985;12:822-7.

63. Bräggger U. Digital imaging in periodontal radiography. J Clin Periodontol 1988;15:551-7.

64. McDavid WD, Dove SB, Welander U, Tronje G. Direct digital extraoral radiography of the head and neck with a solid-state linear x-ray detector. Oral Surg Oral Med Oral Pathol 1992;74:811-7.

65. Mouyen F, Benz C, Sonnabend E, Lodter JP. Presentation and physical evaluation of RadioVisioGraphy. Oral Surg Oral Med Oral Pathol 1989;68:238-42.

66. Mairgunther RH. Film-less digital x-ray image processing--new prospects with the RadioVisioGraphy equipment [Abstract]. Schweiz Monatsschr Zahnmed 1994;104:31-4.

67. Soh G, Loh F, Chong Y. Radiation dosage of a dental imaging system. Quintessence Int 1993;24:189-91.

68. Kircos LT, Giger ME, Yin FF, Doi K, Khademi JK. Comparison of the image receptor characteristics of the RVG with D- and E-speed film [Abstract]. Dentomaxillofac Radiology 1992;21:171.

69. Benz C, Mouyen F. Evaluation of the new RadioVisioGraphy system image quality. Oral Surg Oral Med Oral Pathol 1991;72:627-31.

70. Chen S, Hollander L. Detector response and exposure control of the RadioVisioGraphy system (RVG 32000 ZHR). Oral Surg Oral Med Oral Pathola 1993;76:104-11.

71. Shearer AC, Horner K, Wilson NHF. Radiovisiography for imaging root canals: an *in vitro* comparison with conventional radiography. Quintessence Int 1990;21:789-94.

72. Shearer AC, Horner K, Wilson NHF. Radiovisiography for length estimation in root canal treatment: an *in vitro* comparison with conventional radiography. Int Endod J 1991;24:233-9.

73. Leddy BJ, Miles DA, Newton CW, Brown, CE. Interpretation of endodontic file lengths using RadioVisioGraphy. J Endod 1994;20:542-5.

74. Yokota ET, Miles DA, Newton CW, Brown CE Jr. Interpretation of periapical lesions using RadioVisioGraphy. J Endod 1994;20:490-4.

75. Welander U, Nelvig P, Tronje G, et al. Basic technical properties of a system for direct acquisition of digital intraoral radiographs. Dentomaxillofac Radiol 1992;21:222.

76. Nelvig P, Wing K, Welander U. Sens-A-Ray: a new system for direct digital intraoral radiography. Oral Surg Oral Med Oral Pathol 1992;74:818-23.

77. McDonnell D, Price C. An evaluation of the Sens-A-Ray digital dental imaging system. Dentomaxillofac Radiol 1993;22:121-6.

78. Wenzel A. Sensor noise in direct digital imaging (the RadioVisioGraphy, Sens-A-Ray, and Visualix/Vixa systems) evaluated by subtraction radiography. Oral Surg Oral Med Oral Pathol 1994;77:70-4.

79. Sandorink GCH, Stheeman SE, Huiskens R, Chin D. An ROC study on the effect of image quality in determining root-canal length: a comparison of RVG, Visualix and Ektaspeed film [Abstract]. Dentomaxilofac Radiol 1992:21:222.

80. Scarfe WC, Farman AG, Kelly MS. Flash Dent: an alternative charge-coupled device/scintillator-based direct digital intraoral radiographic system. Dentomaxillofac Radiol 1994;23:11-7.

81. Sanderink GCH, Huiskens R, van der Stelt PF, Welander US, Stheeman SE. Image quality of direct digital intraoral x-ray sensors in assessing root canal length. Oral Surg Oral Med Oral Pathol 1994;78:125-32.

82. Boynton RM. Human color vision. Los Angeles: PK Kaiser, 1992:2-154.

83. Hakfoort C. Newton's optics: the changing spectrum of science. In: Let Newton Be! New York: Oxford University Press, 1988:81-100.

84. Dykema RW, Goodacre CJ, Phillips RW. Johnston's modern practice in fixed prosthodontics, 4th ed. Philadelphia: WB Saunders, 1986:330-40.

85. Warren RM, Warren RP. Helmholtz on perception: its physiology and development. New York: John Wiley & Sons, 1968:61-168.

86. Koenigsberger L. Hermann von Helmholtz. New York: Dover Publications, 1965:235.

87. Hurvich LM. Color Vision. Sunderland, Mass: Sinauer Associates, 1981:1-131.

88. Munsell AH. A color notation. Baltimore: Munsell Color Co., 1975. Cited in: Dykema RW, Goodacre CJ, Phillips RW. Johnston's modern practice in fixed prosthodontics. 4th ed. Philadelphia: WB Saunders, 1986:330-40.

89. Alfano B, Brunetti A, Ciarrmiello A, Salvatore M. Simultaneous display of multiple MR parameters with "quantitative magnetic color imaging." J Comput Assist Tomogr 1992:16:634-40.

90. Kremkau FW. Doppler color imaging. Principles and instrumentation. Clin Diagn Ultrasound 1992;27:7-60.

91. Bluth EI, Merritt CR. Doppler color imaging. Carotid and vertebral arteries. Clin Diagn Ultrasound 1992;27:61-96.

92. Pellerito JS, Taylor KJ. Doppler color imaging. Peripheral arteries. Clin Diagn Ultrasound 1992;27:97-112.

93. Schoning M, Grunert D. Hassler W, Voigt K, Michaelis R. Demonstration of giant MCA aneurysm by transcranial duplex sonography and color Doppler imaging. Childs Nerv System 1993;9:110-4.

94. Dougherty MJ, Hallett JW Jr, Naessens JM, et al. Optimizing technical success of renal revascularization: the impact of intraoperative color-flow duplex ultrasonography. J Vasc Surg 1993;17:849-56.

95. Spreafico C, Frigerio L, Lanocita R, et al. Color-Doppler ultrasound in ovarian masses: anatomo-pathologic correlation. Tumori 1993;79:262-7.

96. Miyagi Y, Masaoka H, Akamatsu N, Sekiba K. Development of a three-dimensional color Doppler system. Med Prog Technol 1993;18:201-8.

97. Russ, JC. The Image Processing Handbook. Boca Raton, Fla.: CRC Press, 1992:5-111.

98. Andrews HC, Tescher AG, Kruger RP. Image processing by digital computer. IEEE Spectrum 1972;9:20-32. Cited in: Crooks IC, Fallone BG. Contrast enhancement of portal images by selective histogram equalization. Med Phys 1993;20:199-204.

99. Crooks I, Fallone BG. Contrast enhancement of portal images by selective histogram equalization. Med Phys 1993;20:199-204.

100. Analoui M. Personal communication, 1994.

101. Hall EL. Almost uniform distributions for computer image enhancement. IEEE Trans Comput 1974;C-23:207-8.

102. Verdonschot EH, Kuijpers JMC, Polder BJ, DeLeng-Worm MH, Bronkhorst EM. Effects of digital grayscale modification on the diagnosis of small approximal carious lesions. J Dent 1992;20:44-49.

103. Wenzel A, Verdonschot EH, Truin GJ, Konig KG. Accuracy of visual inspection, fiberoptic transillumination, and various radiographic image modalities for the detection of occlusal caries in extracted non-cavitated teeth. J Den Res 1992;71:1934-37.

104. Engh CA, McGovern TF, Schmidt LM. Roentgenographic densitometry of bone adjacent to a femoral prosthesis. Clin Orthoped Rel Res 1993;292:177-190.

105. Pizer SM, Zimmerman JB, Staab EV. Adaptive grey level assignment in CT scan display. J Comput Assist Tomogr 1984;8:300-5.

106. Verellen D, DeNeve W, Van den Heuvel F, Coghe M, Louis O, Storme G. On-line portal imaging: image quality defining parameters for pelvic fields--a clinical evaluation [Abstract]. Int J Radiat Oncol Biol Phys 1993;27:945-52.

107. Rosenman J, Roe CA, Cromartie R, Muller KE, Pizer SM. Portal film enhancement: technique and clinical utility [Abstract]. Int J Radiat Oncol Biol Phys 1993;25:333-8.

108. Braunstein EM, Capek P, Buckwalter K, Bland P, Meyer CR. Adaptive Histogram Equalization in digital radiography of destructive skeletal lesions. Radiology 1988;166:883-5.

109. Lehr JL, Capek P. Histogram equalization of CT images. Radiology 1985;154:163-9.

110. Pizer SM, Chan FH. Evaluation of the number of discernable levels produced by a display. Information processing in medical imaging (Proceeds of the VIth International Conference on Information Processing in Medical Imaging: Paris, France, July 1979) INSERM, 1980. Cited in: Lehr JL, Capek P. Histogram equalization of CT images. Radiology 1985;154:163-9.

111. Rehm K, Seeley GW, Dallas WJ, Ovitt TW, Seeger JF. Design and testing of artifact-suppressed adaptive histogram equalization: a contrast-enhancement technique for display of digital chest radiographs. J Thorac Imag 1990;5:85-91.

112. Abercrombie MLJ. The anatomy of judgement. London: Free Association Books, 1989:25-91.

113. Galagan DJ, Vermillion J. Diagnosis of caries by radiographic interpretation. J Dent Res 1956;35:33-8. Cited in: Goldstein IL, Mobley WH, Chellemi SJ. The observer process in the visual interpretation of radiographs. J Dent Educ 1971;35:485-91.

114. Garland LH. On the scientific evaluation of diagnostic procedures. Radiology 1949;52:309-29.

115. Fletcher CM, Oldham PD.The problem of consistent radiological diagnosis in coalminers' pneumoconiosis. Brit J Industr Med 1949;6:168-83.

116. Yerushalmy J, Garland LH, Harknes JT, et al. An evaluation of the role of serial chest roentgenograms in estimating the progress of disease in patients with pulmonary tuberculosis. Amer Rev Tuberculosis 1951;64:225-48.

117. Koran LM. The reliability of clinical methods, data and judgments. I N Engl J Med 1975;293:642-6.

118. Koran LM. The reliability of clinical methods, data and judgments. II N Engl J Med 1975;293:695-701.

119. Goldstein IL, Mobley WH. Error and variability in the visual processing of dental radiographs. J Applied Psychol 1971;55:549-53.

120. Goldman M, Pearson AH, Darzenta N. Endodontic success - Who's reading the radiograph? Oral Surg Oral Med Oral Pathol 1972;33:432-7.

121. Goldman M, Pearson AH, Darzenta N. Reliability of radiographic interpretations. Oral Surg Oral Med Oral Pathol 1974;38:287-93.

122. Duinkerke ASH, Van de Poel ACM, DeBoo T, Doesburg WH. Variations in the interpretation of periapical radiolucencies. Oral Surg Oral Med Oral Pathol 1975:40:414-21.

123. Nielsen J. Reliability in reading endodontic radiographs. J Dent Res 1979;58: Special issue D:2296, abstract 27.

124. Antrim DD. Reading the radiograph: a comparison of viewing techniques. J Endod 1983;9:502-5.

125. Zakariasen KL, Scott DA, Jensen JR. Endodontic recall radiographs: how reliable is our interpretation of endodontic success and failure and what factors affect our reliability? Oral Surg Oral Med Oral Pathol 1984;57:343-7.

126. Gelfand M, Sunderman EJ, Goldman M. Reliability of radiographic interpretations. J Endod 1983;9:71-5.

127. Wahab MHA, Greenfield TA, Swallow JN. Interpretation of intraoral periapical radiographs. J Dent 1984;12:302-13.

128. Brynolf I. Roentgenologic periapical diagnosis I. Reproducibility of interpretation. Swed Dent J 1970;63:339-44.

129. Brynolf I. Roentgenologic periapical diagnosis II. One, two or more roentgenograms? Swed Dent J 1970;63:345-50.

130. Brynolf I. Improved viewing facilities for better roentgenographic diagnosis. Oral Surg Oral Med Oral Pathol 1971;32:808-11.

131. Welander U, McDavid WD, Higgins NM, Morris CR. The effect of viewing conditions on the peceptibility of radiographic details. Oral Surg Oral Med Oral Pathol 1983;56:651-4.

132. Kundel HL, Wright DJ. The influence of prior knowledge on visual search strategies during the viewing of chest radiographs. Radiology 1969;93:315-20.

133. Herman PG, Hessel SJ. Accuracy and its relationship to experience in the interpretation of chest radiographs. Invest Radiol 1975;10:62-7.

134. Tuddenham, WJ. Visual search, image organization, and reader error in roentgen diagnosis. Studies of the psychophysiology of roentgen image perception. Radiology 1962;78:694-704.

135. Gröndahl, HG. Some factors influencing observer performance in radiographic caries diagnosis. Swed Dent J 1979;3:157-72.

136. Schreiber MH. The clinical history as a factor in roentgenogram interpretation. J Amer Med Assoc 1963;185:399-401.

137. Swensson RG, Hessel SJ, Herman PG. Omissions in radiology: faulty search or stringent reporting criteria? Radiology 1977;123:563-7.

138. Koran LM. Increasing the reliability of clinical data and judgments. Annals Clin Res 1976;8:69-73.

139. Brynolf I. Radiography of the periapical region as a diagnostic aid II. Diagnosis of pulp-related changes. Dent Radiogr Photogr 1979;52:25-47.

140. Valachovic RW, Douglass CW, Berkey CS, McNeil BJ, Chauncey HH. Examiner reliability in dental radiography. J Dent Res 1986;65:432-6.

141. Eckerbom M, Andersson J-E, Magnusson T. Interobserver variation in radiographic examination of endodontic variables. Endod Dent Traumatol 1986;2:243-6.

142. Adobe Systems, Inc. Adobe Photoshop users guide. Mountain View: Adobe Systems, Inc., 1993:103.

143. Eckert, G. Personal communication, 1994.

# ABSTRACT

# INTERPRETATION OF CHEMICALLY CREATED PERIAPICAL LESIONS USING DIRECT DIGITAL IMAGING

by

Allen W. Meier

Indiana University School of Dentistry

Indianapolis, Indiana

The purpose of this study was to determine if any of several methods of digital radiographic image enhancement could allow earlier diagnosis of periapical disease than standard grayscale images. Perchloric acid (70 percent) was used to create simulated periapical lesions in tooth sockets of fifteen dentate cadaver jaw specimens. Using the Trophy direct digital radiographic system, digital images were captured at seven selected time intervals from 0 to 24 hours after initial acid application. Each image was then altered in four additional ways: contrast reversal, pseudocolor enhancement and two forms of histogram equalization. A total of 525 images were displayed on a computer monitor for evaluation by five endodontists or endodontic graduate students. Images were

evaluated twice by each rater, with viewings 1-2 weeks apart. Statistical analysis determined the level of interrater variability and intrarater reproducibility, as well as the relative merits of each enhancement technique. Results indicate that at 8, 12, 16 and 24 hours after acid application both techniques of histogram equalization yielded a statistically significant improvement over reverse contrast in perception of periapical pathology. Linear and pseudocolor enhanced images were also significantly more diagnostic than reverse contrast at 12, 16 and 24 hours. Intraevaluator reproducibility showed moderate agreement, but analysis showed only a fair level of interevaluator agreement.

CURRICULUM VITAE

Allen Wesley Meier

| | |
|---|---|
| June 5, 1960 | Born in El Paso, Texas |
| May 1982 | B.S., Taylor University, Upland, Indiana |
| June 11, 1983 | Married Angela Fay Davis |
| May 1990 | D.D.S., Indiana University School of Dentistry, Indianapolis, Indiana |
| July 1990 to July 1991 | Dental General Practice Residency, Scott Air Force Base, Illinois |
| June 3, 1991 | Birth of Daniel Joseph Meier |
| August 1991 to May 1993 | Dental Officer, 384th Medical Group, McConnell Air Force Base, Kansas |
| August 25, 1993 | Birth of Timothy Andrew Meier |
| June 1993 to Present | M.S.D. Program, Endodontics, Indiana University School of Dentistry, Indianapolis, Indiana |

Professional Organizations

American Dental Association
American Association of Endodontists